



The Spencer B. King III
导管室 南京市第一医院
Chief: Prof. Shao-Liang Chen

The 3rd Complex PCI Forum
Nov 30, Lunch Meeting, Room 1, B2
Seoul, South Korea

Switching Strategy

Bill D Gogas MD, PhD, FACC

Interventional Cardiologist | “The Spencer B. King III Cath Lab” | Nanjing | CN

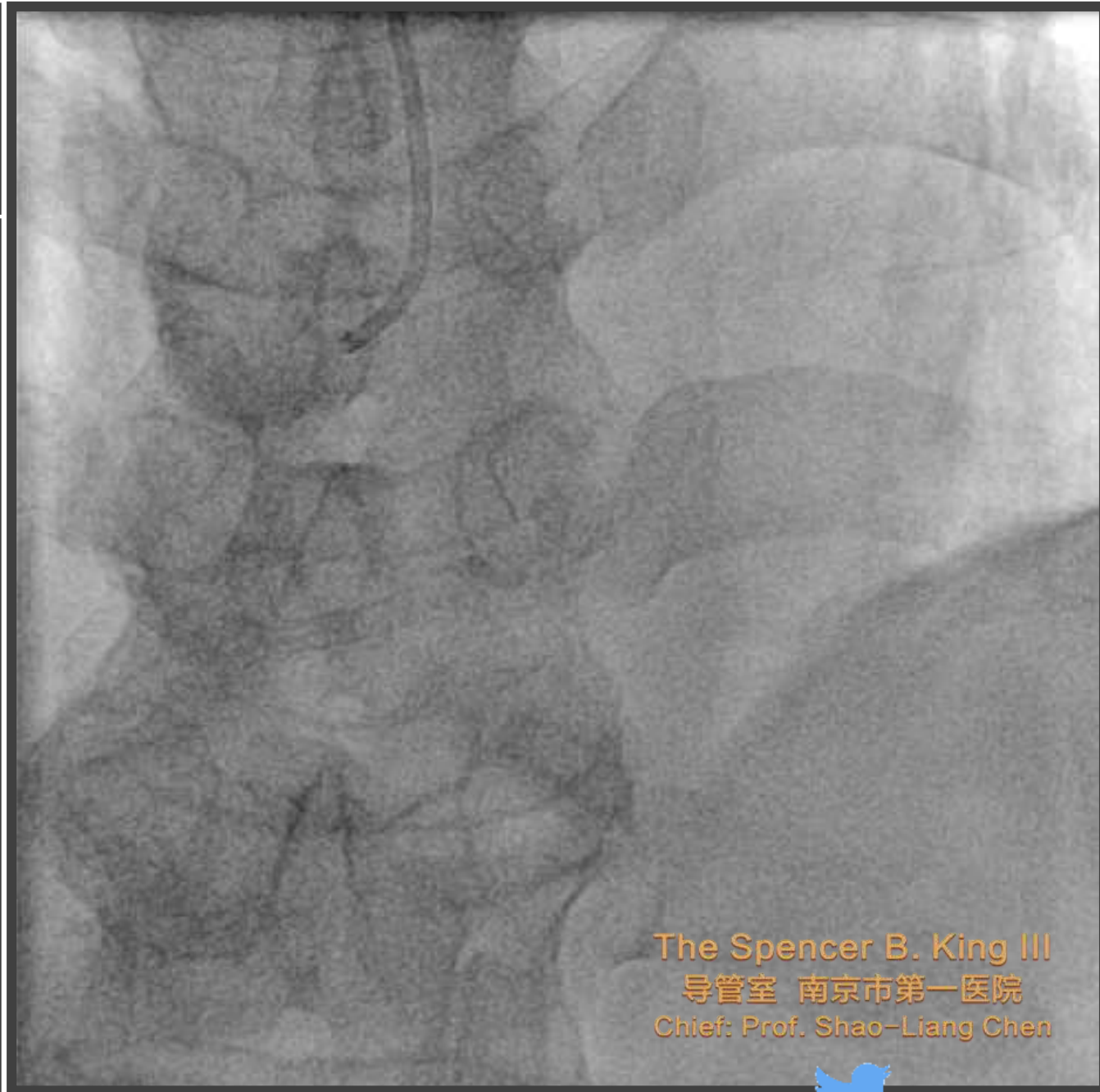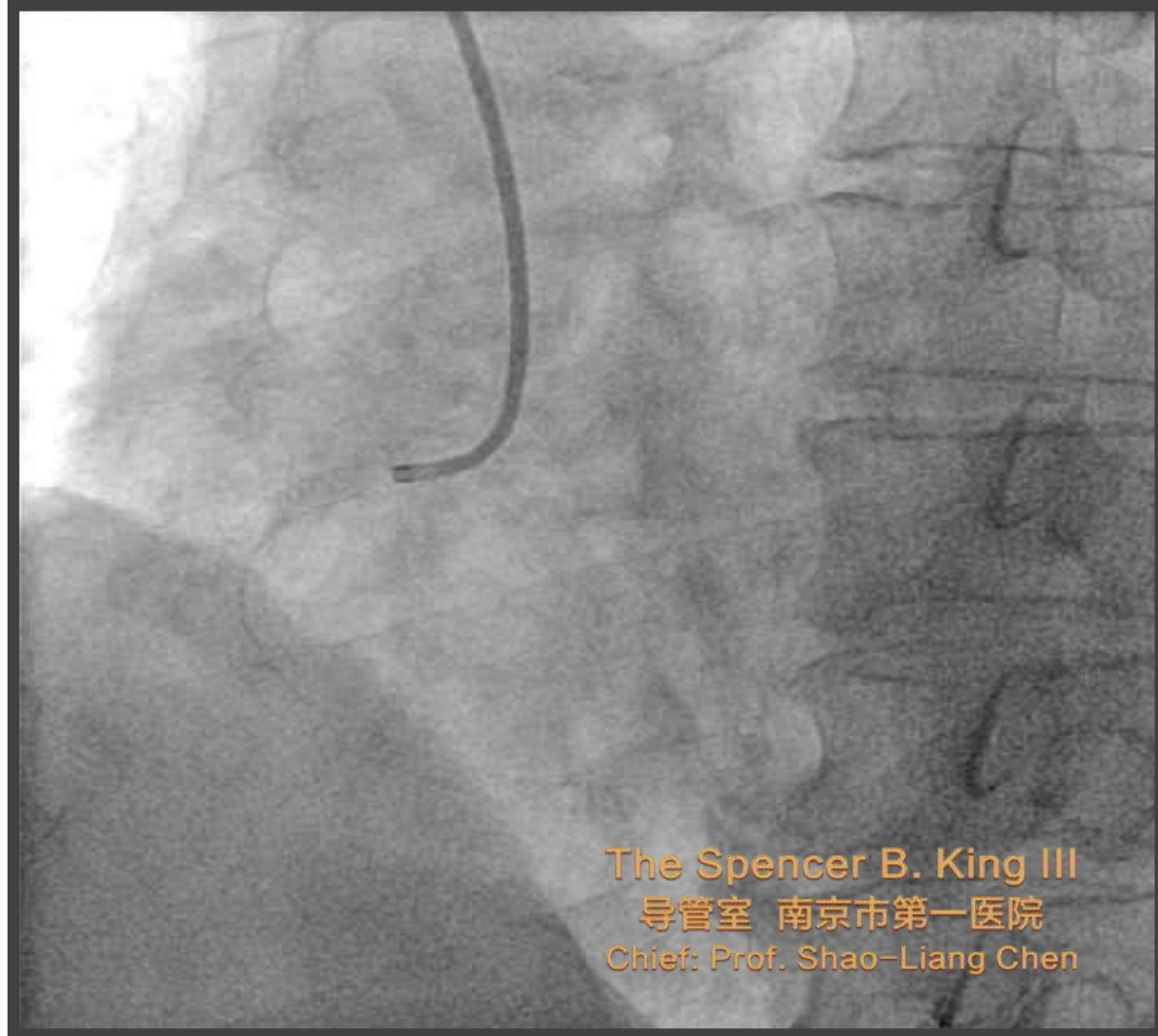
Fmr Instructor of Medicine | Emory University | Atlanta | GA | US

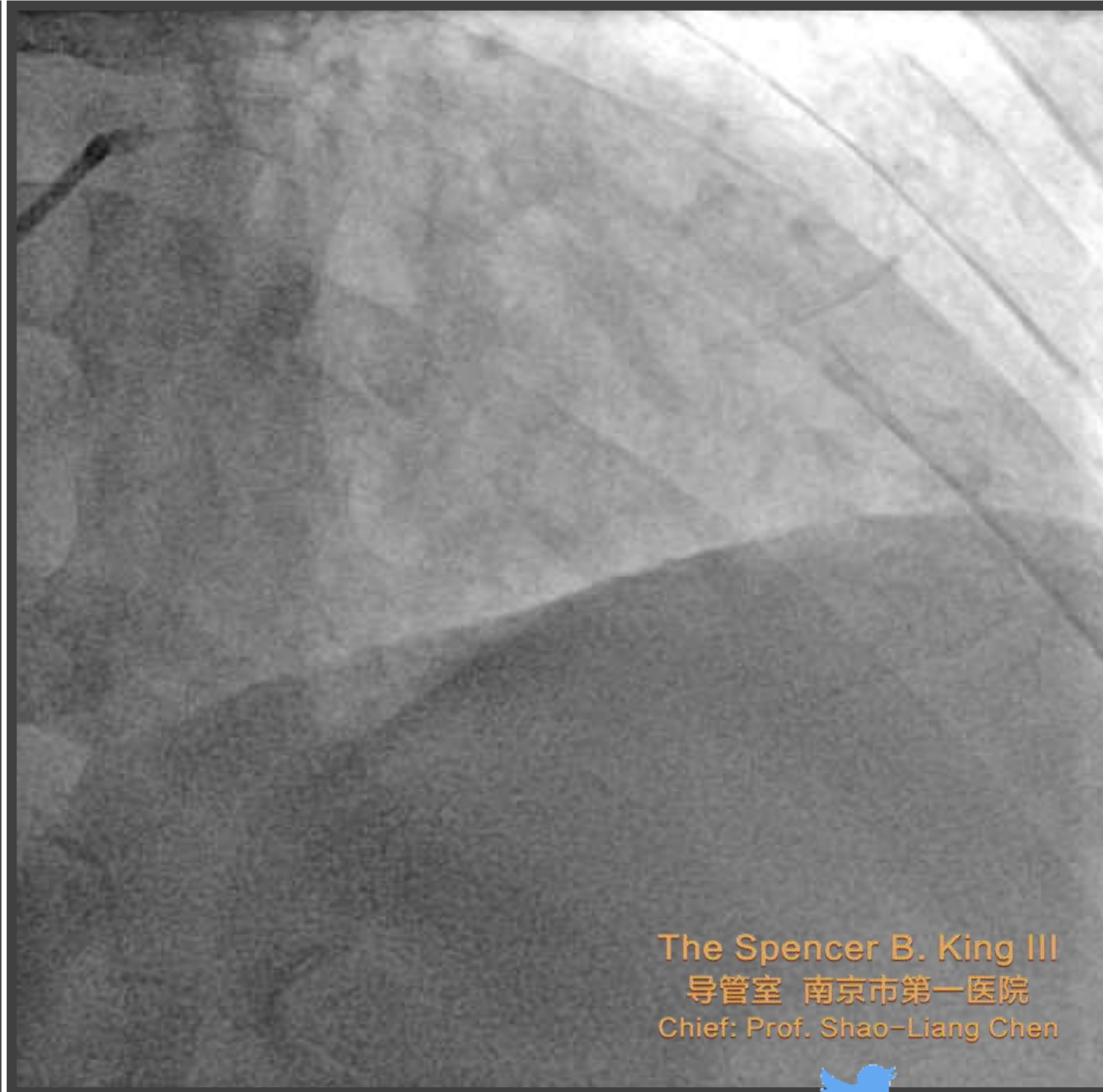
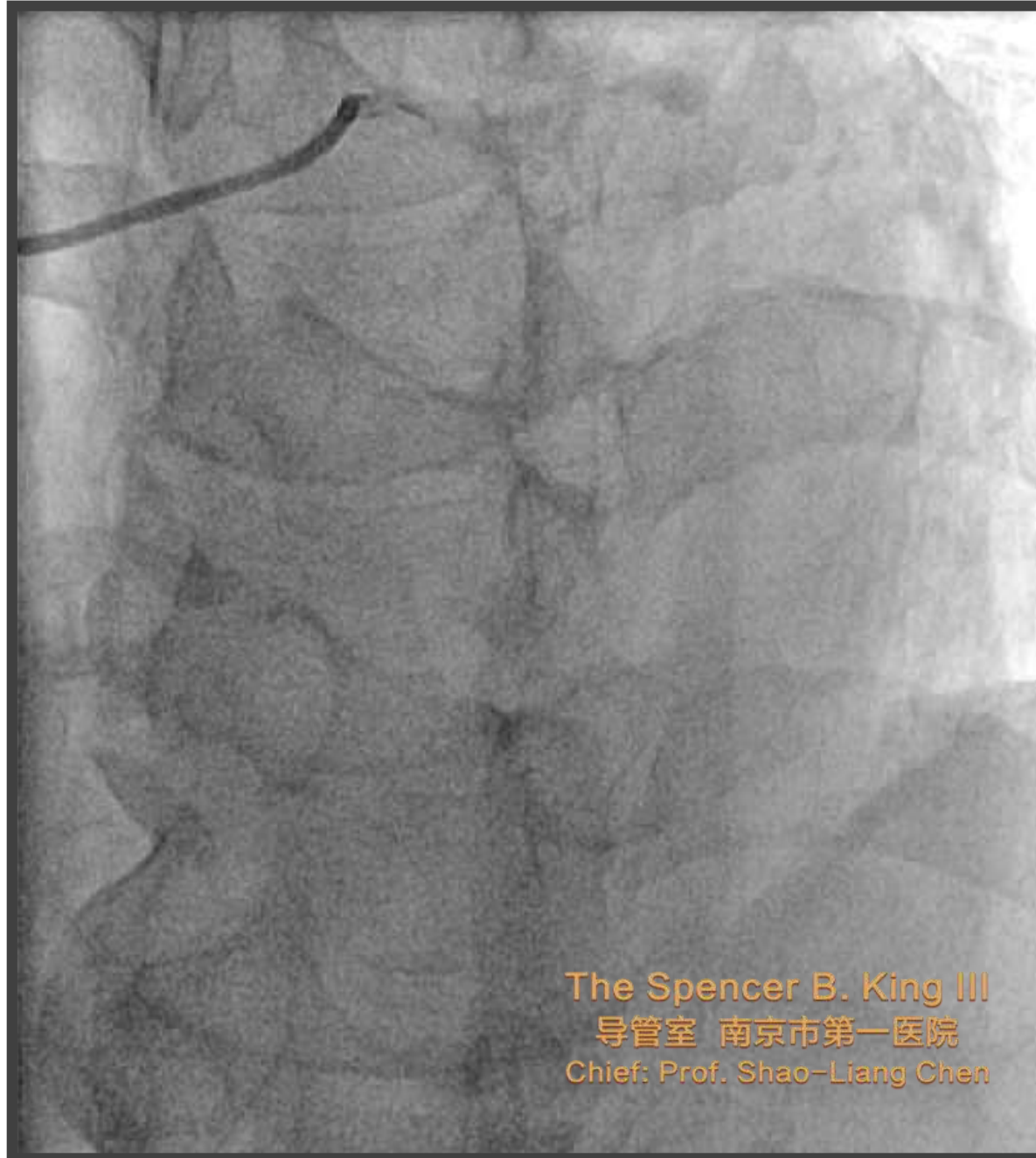Visiting Professor of Medicine | Nanjing Medical University | Nanjing | CN

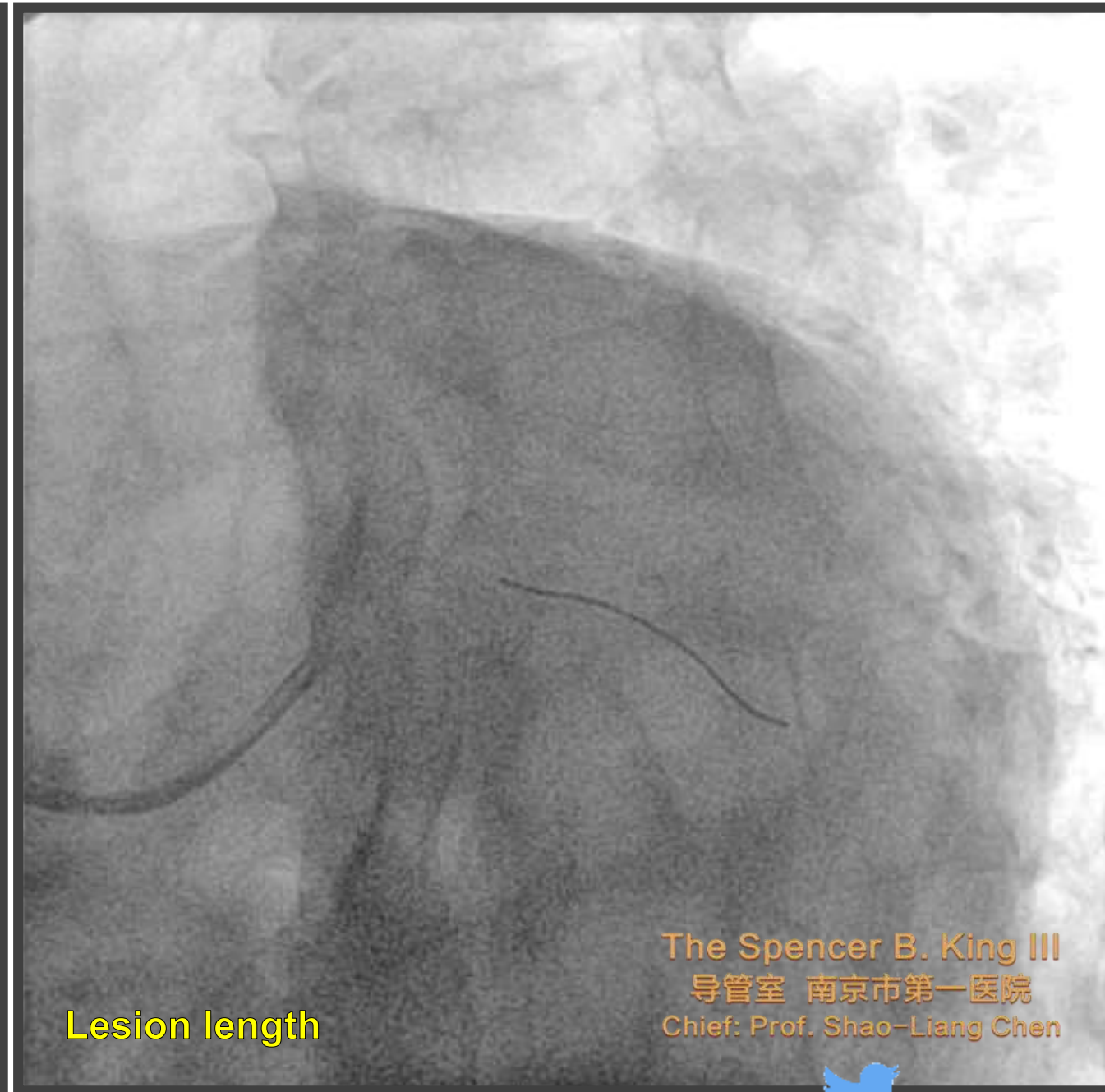
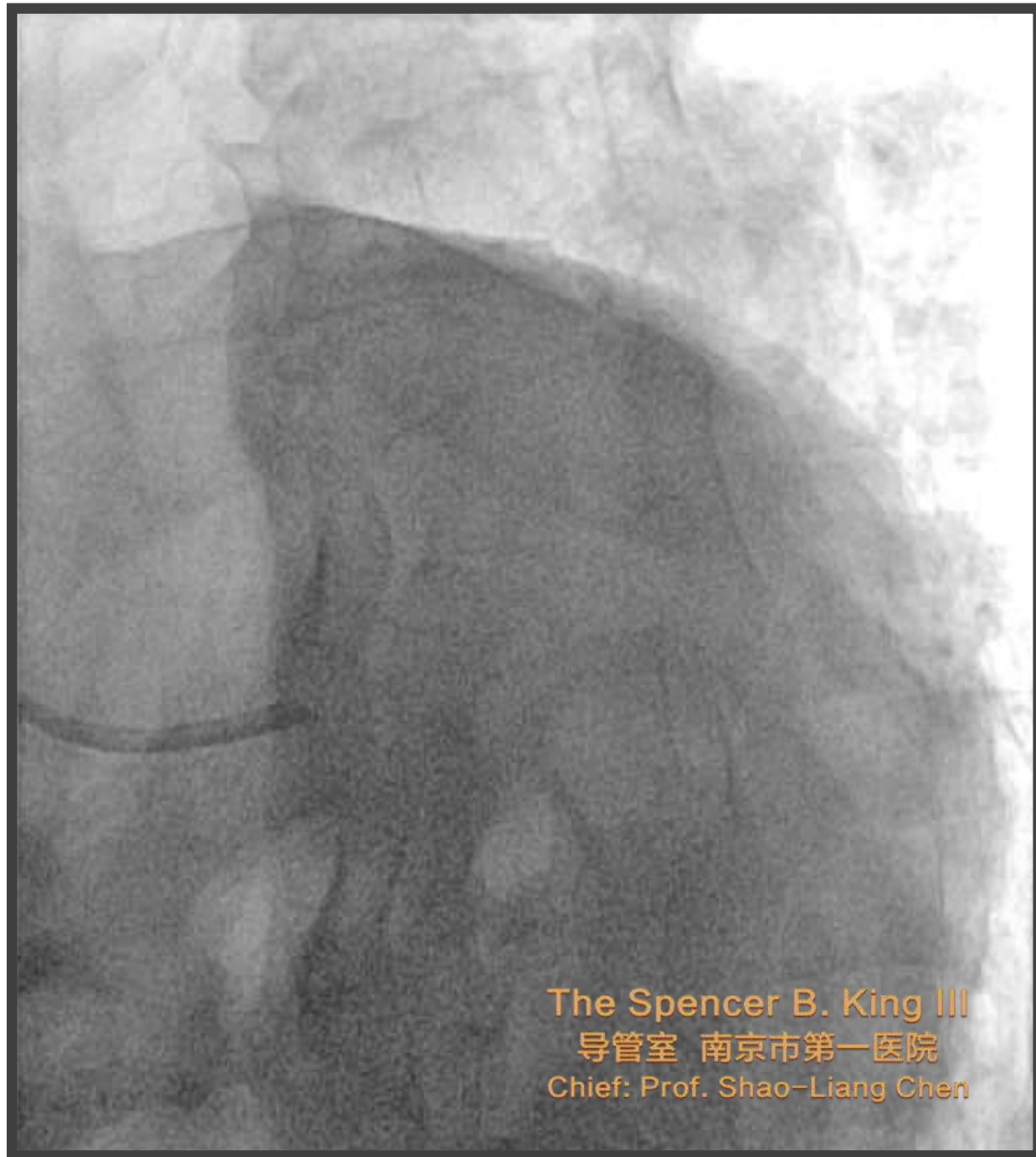
CME/MOC Editor: JACC CV Interventions



M, 77 yo, ACS / DM I, Hypertension
Labs: Tnl 0,063 ng/ml (<0,04ng/ml)
ASA: 100mg x 1, Clopidogrel: 75mg x 1, Losartan:
80mg x 1, Crestor: 10mg x 1, Lopressor: 50mg x 2





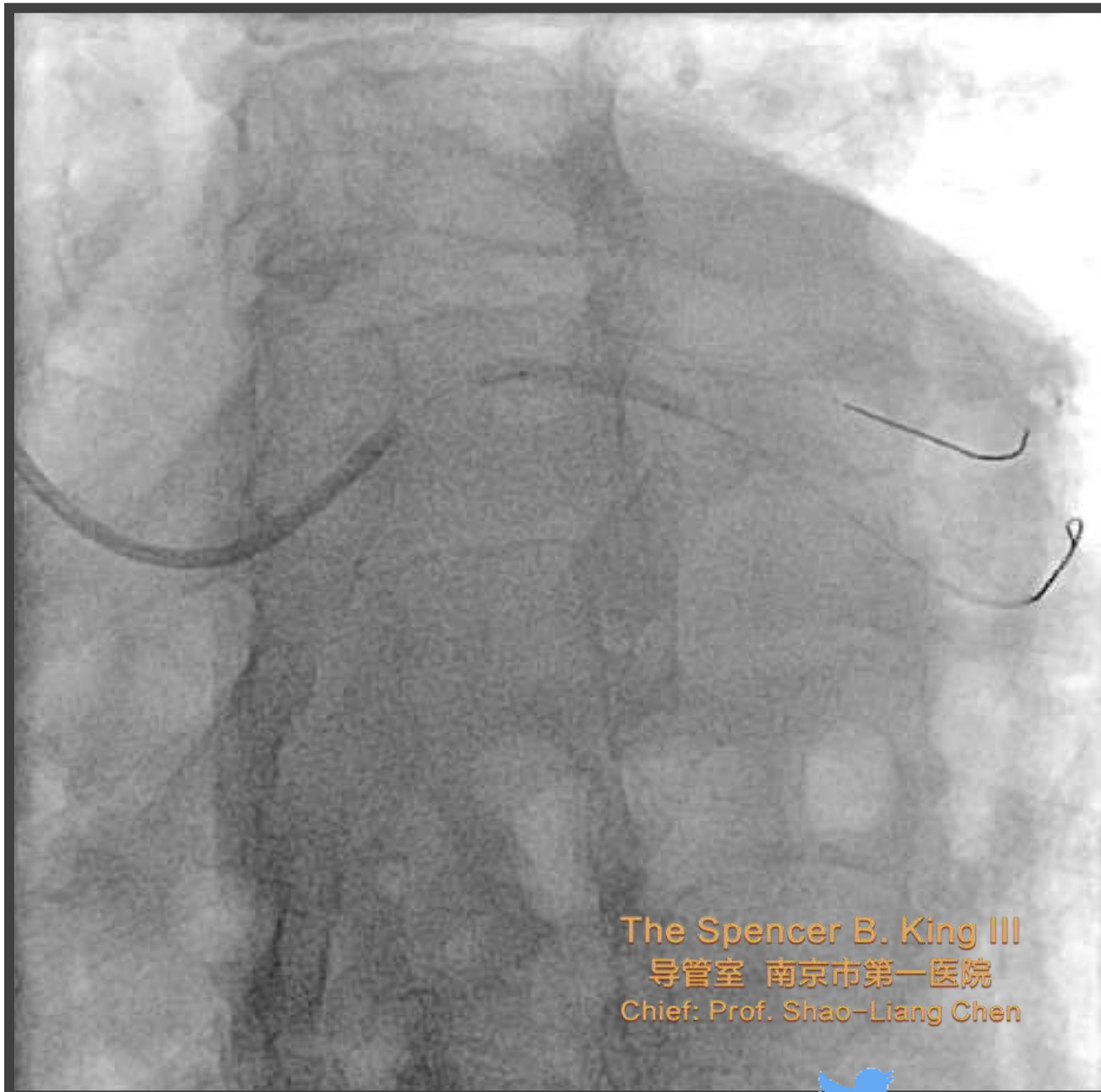
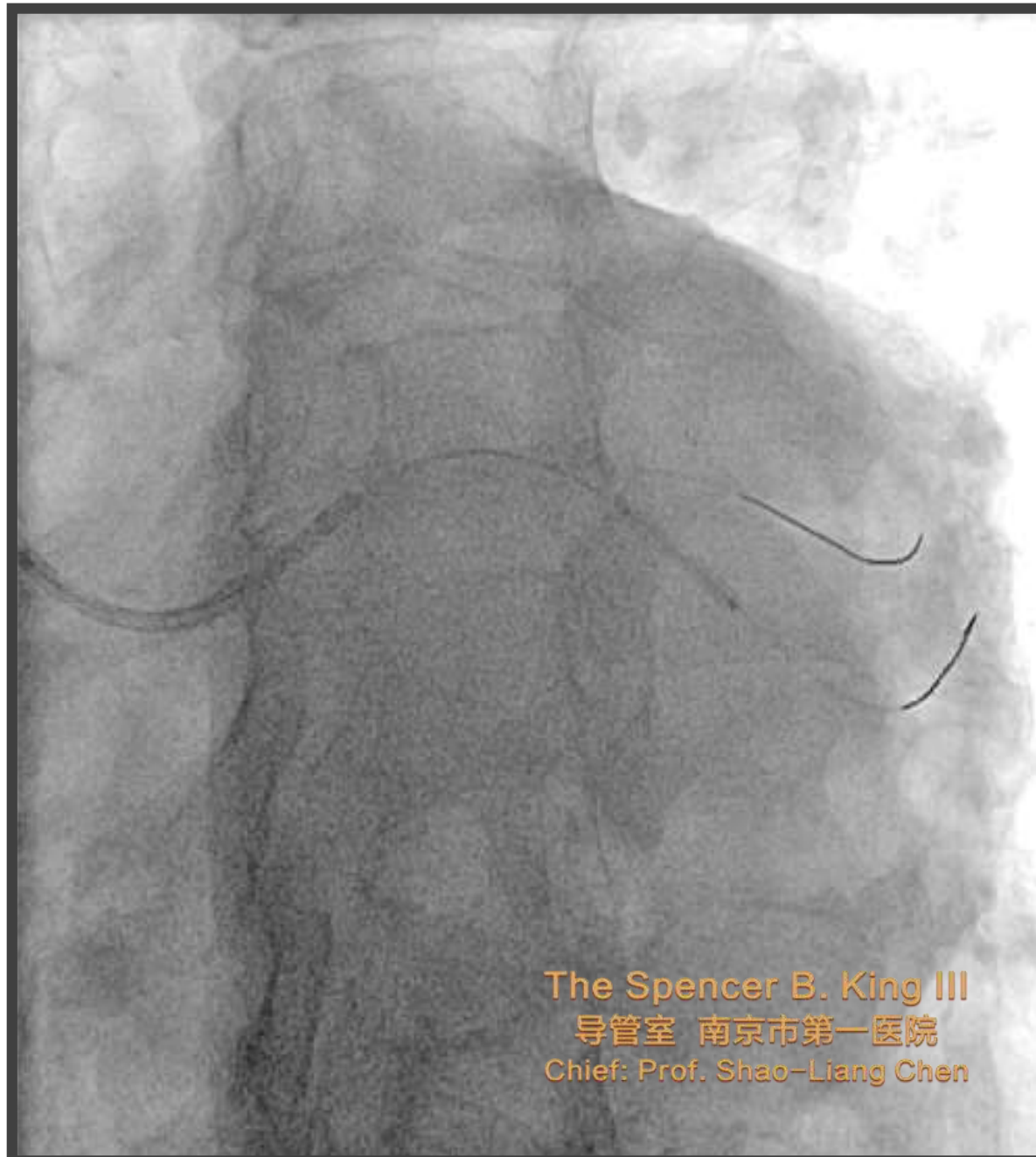
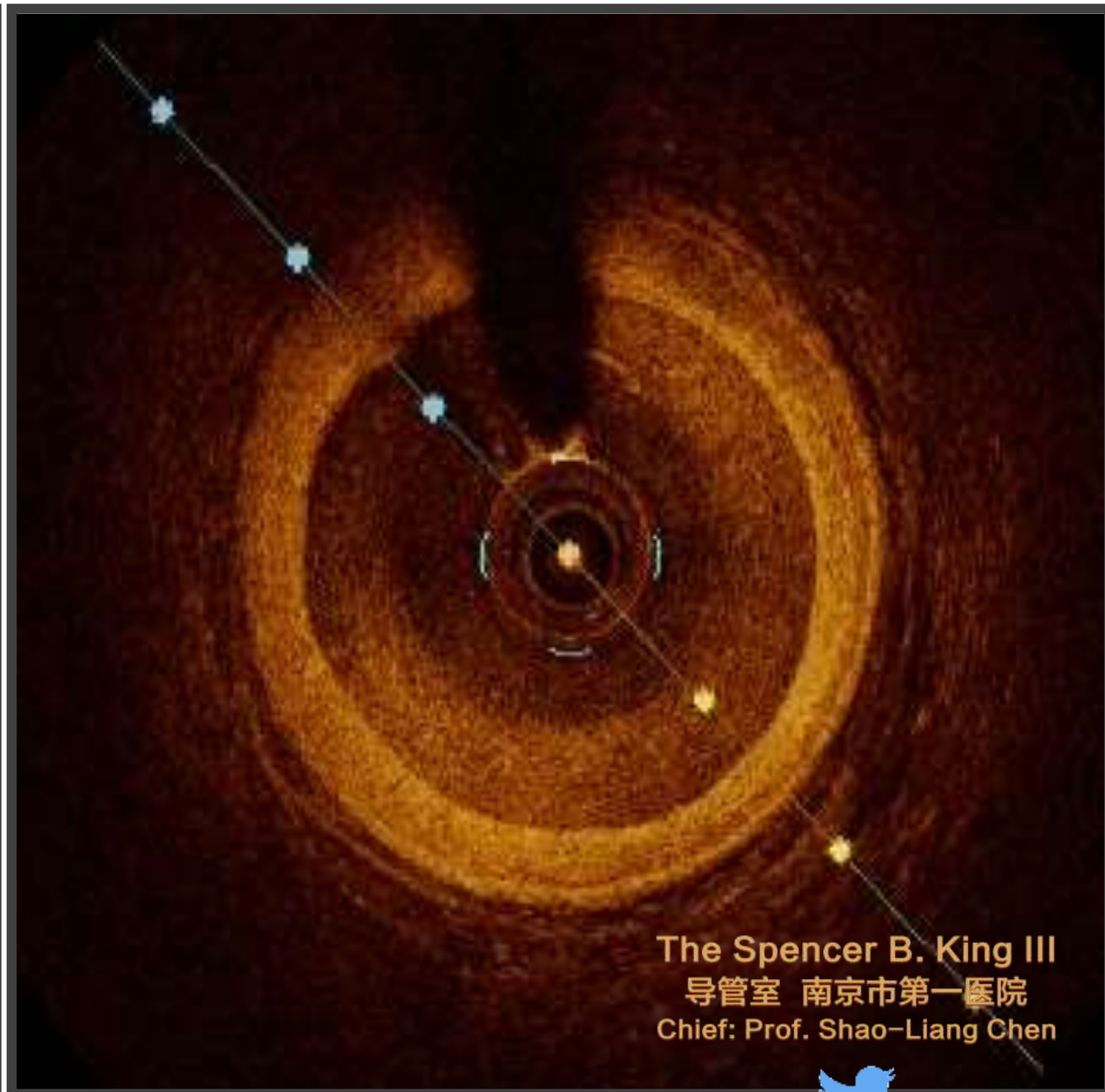


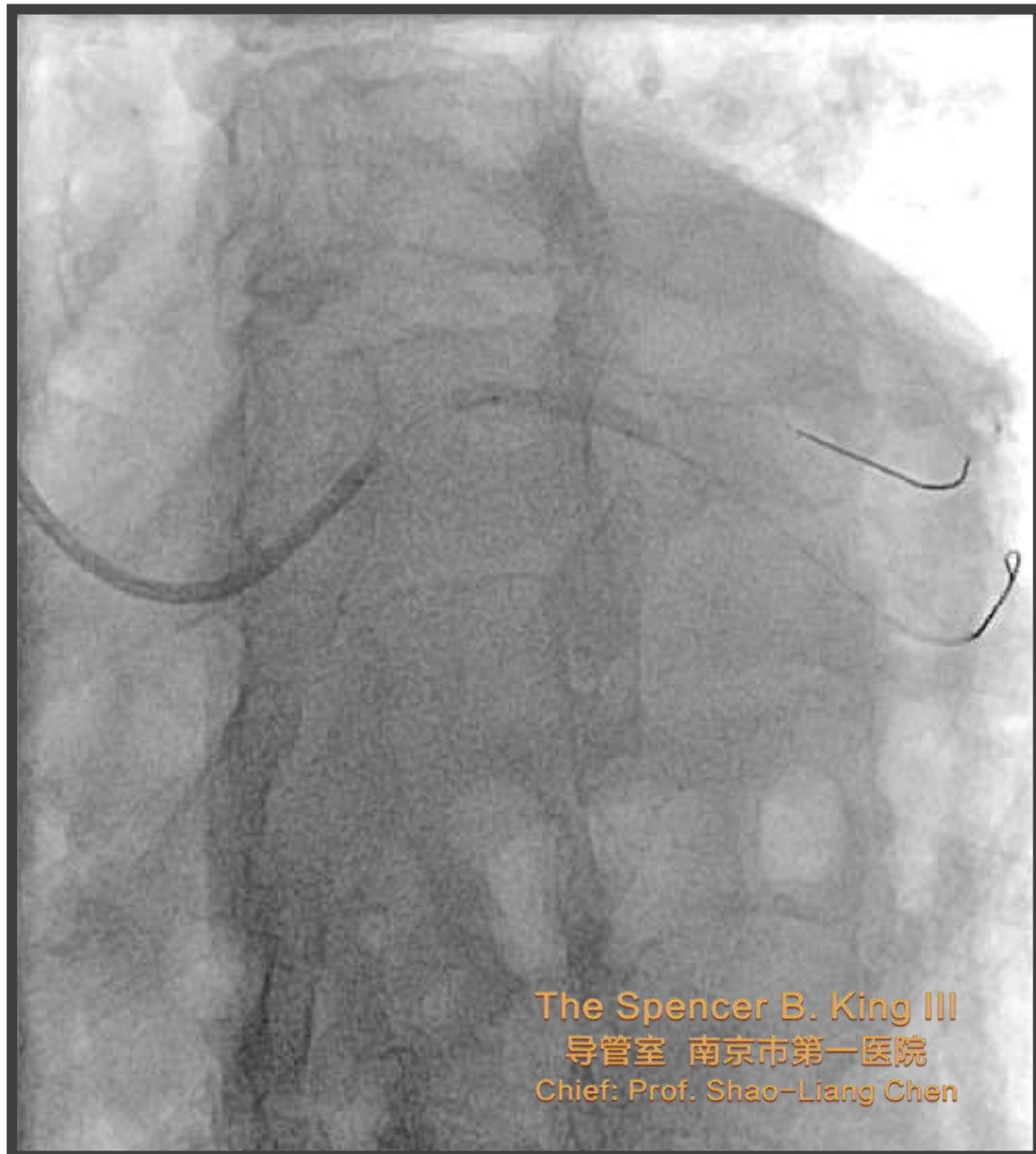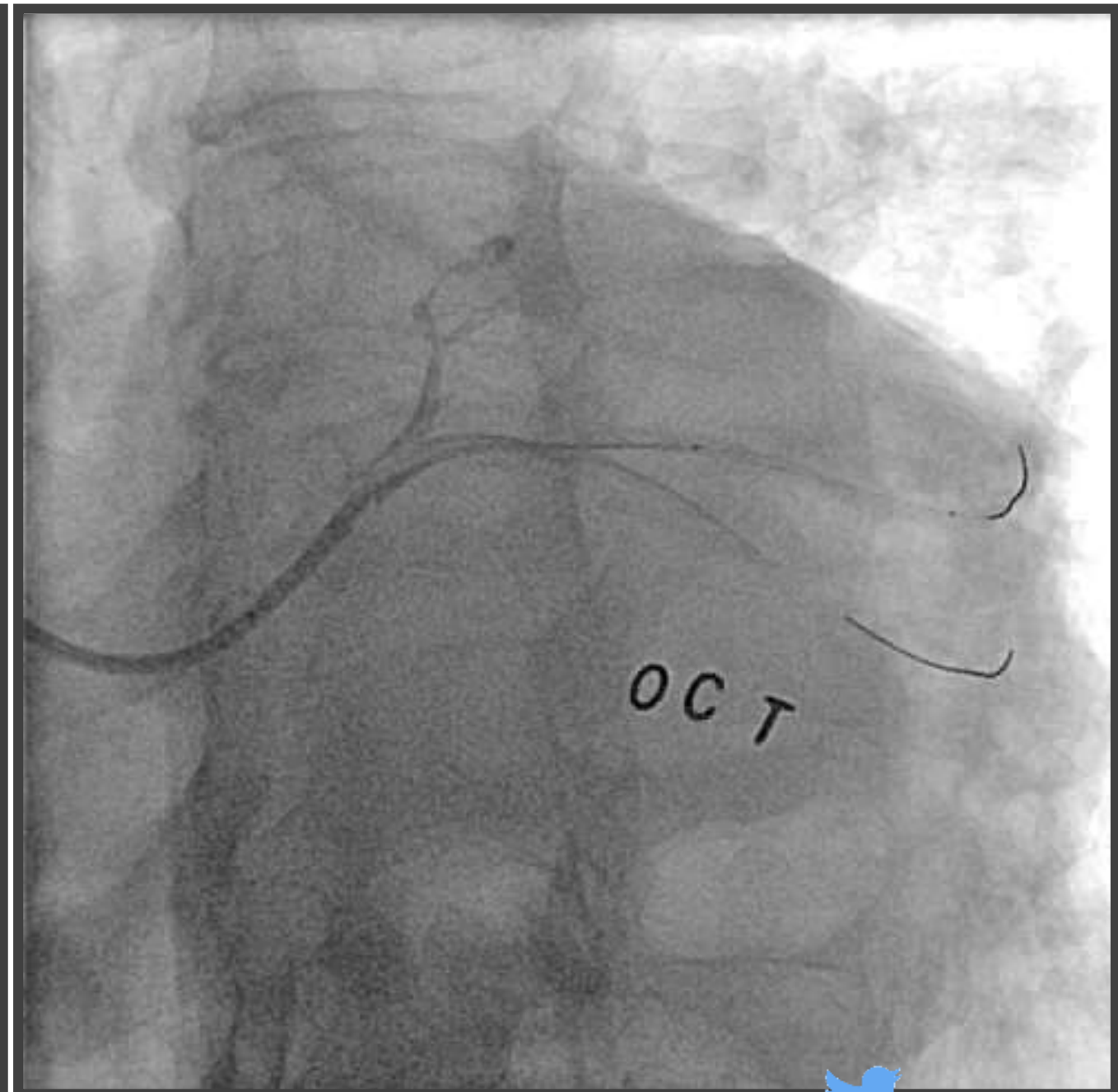
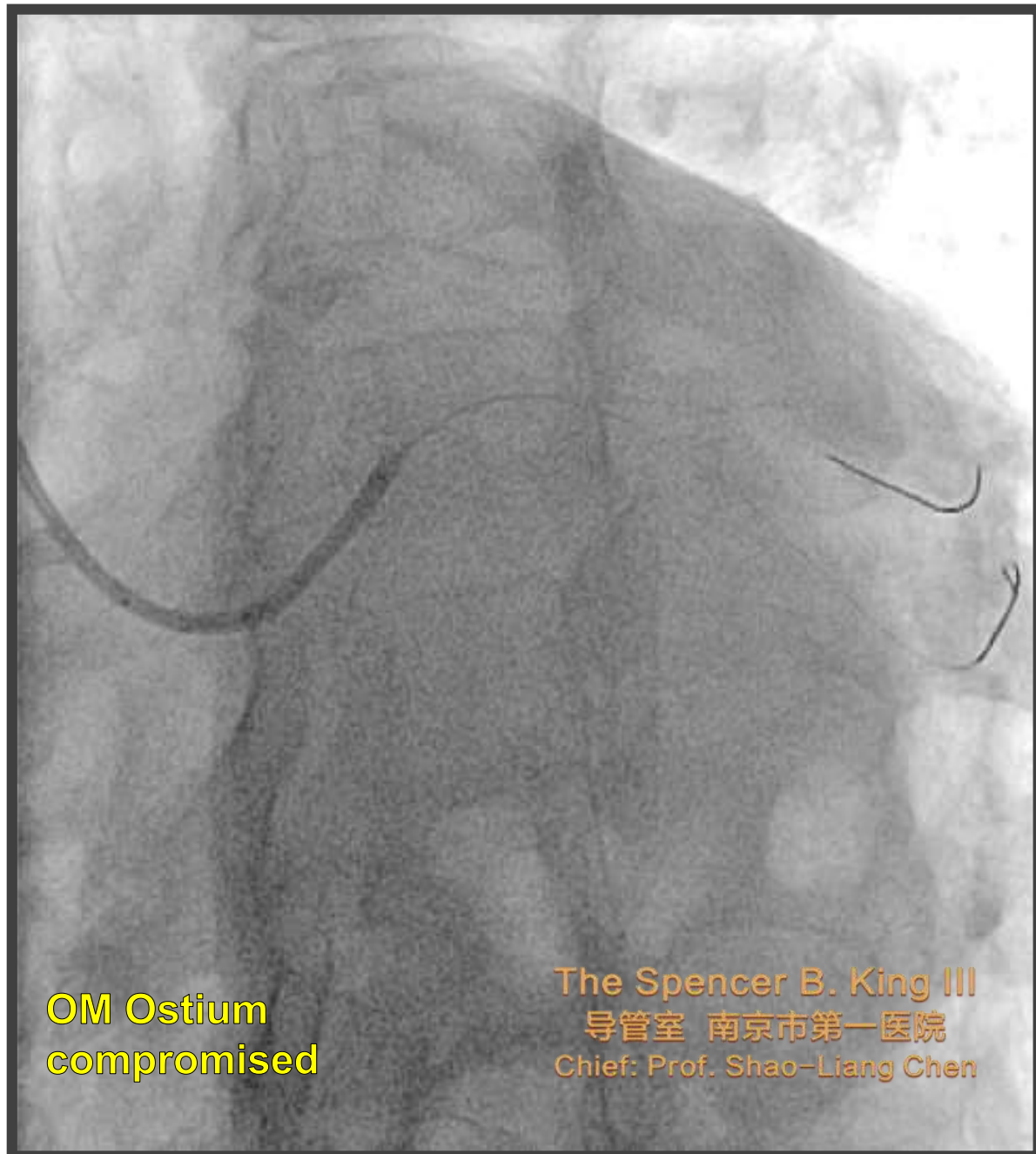The Spencer B. King III
导管室 南京市第一医院
Chief: Prof. Shao-Liang Chen

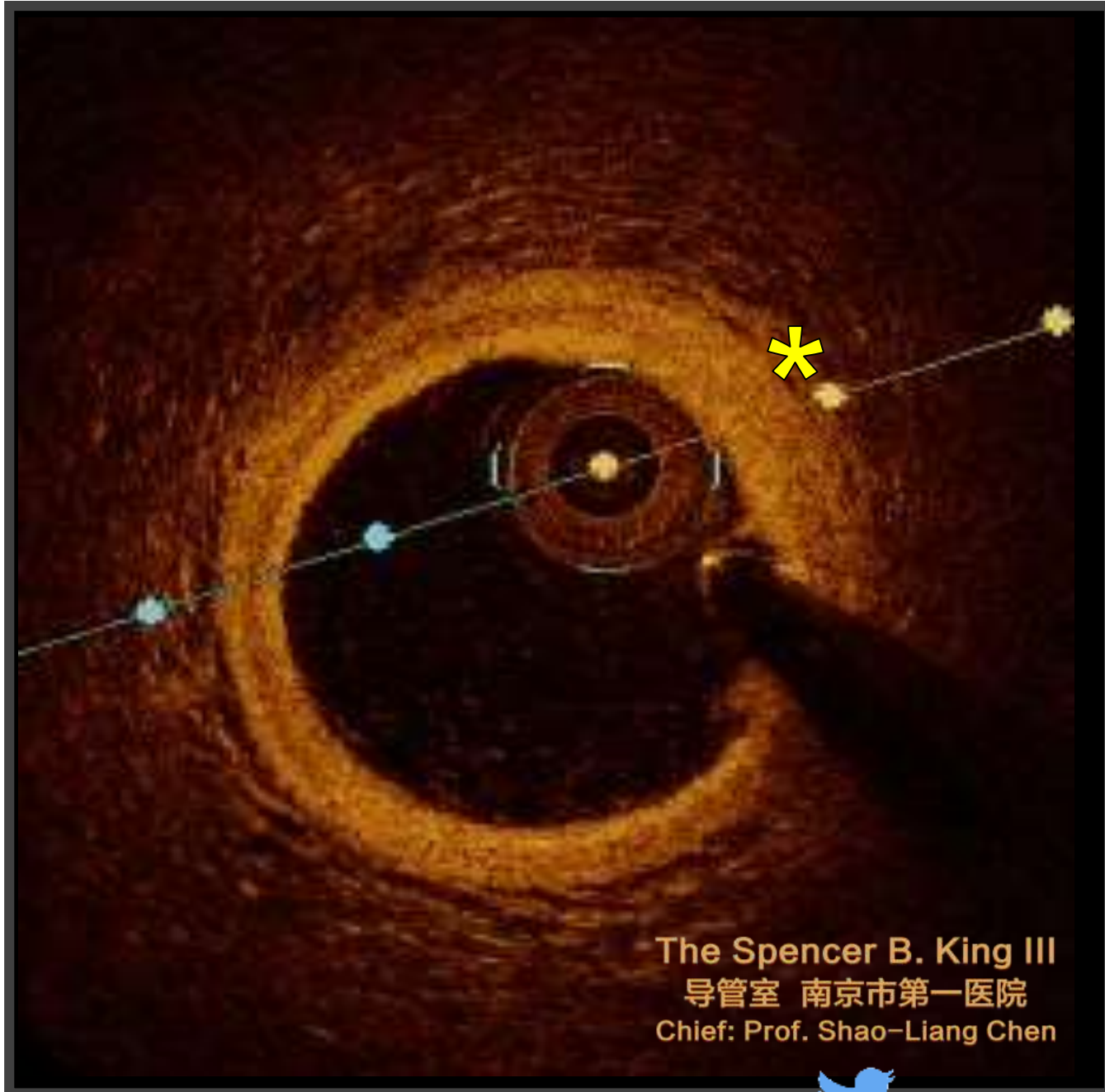
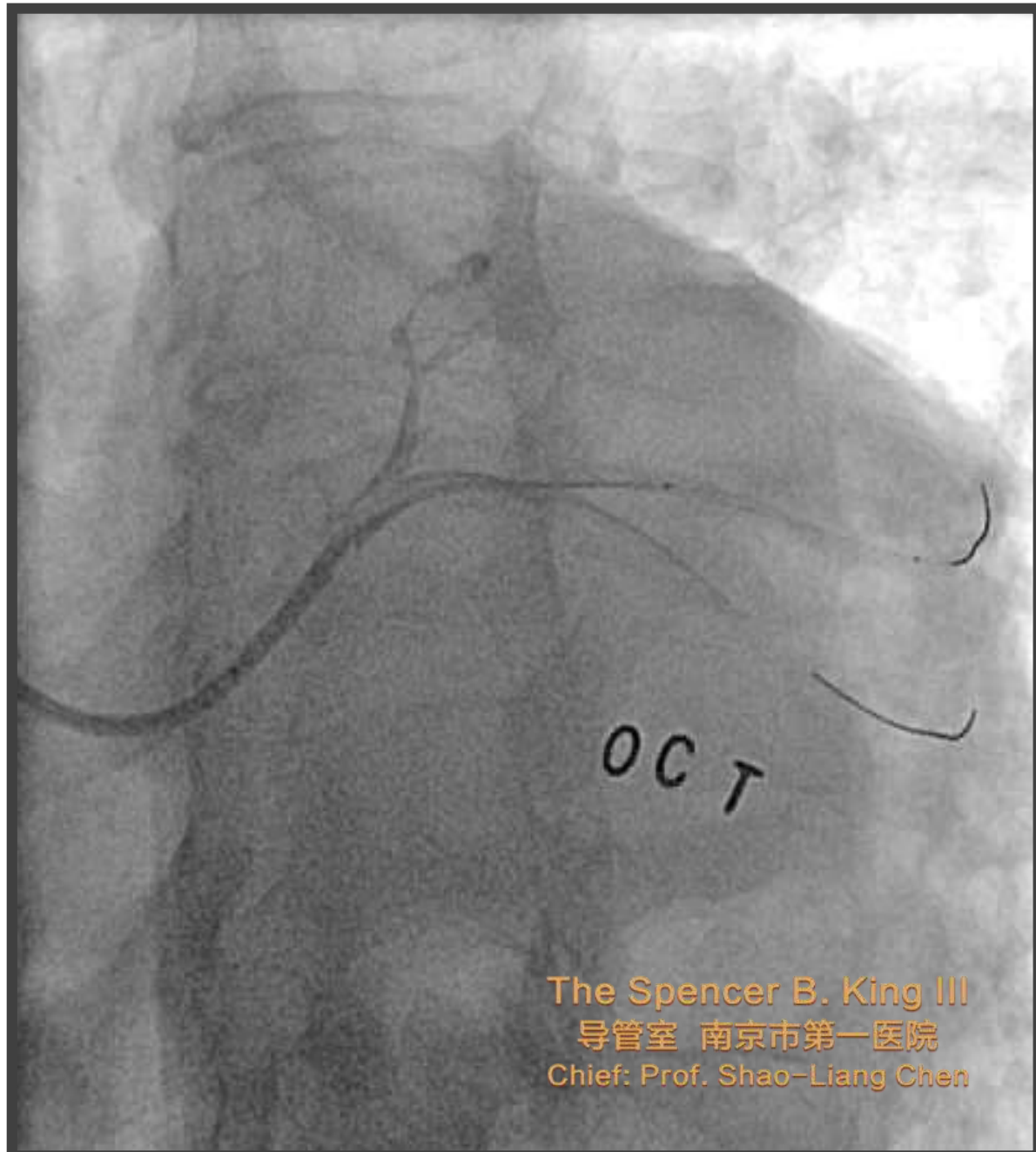
1 Stent Strategy w/ SB Protection

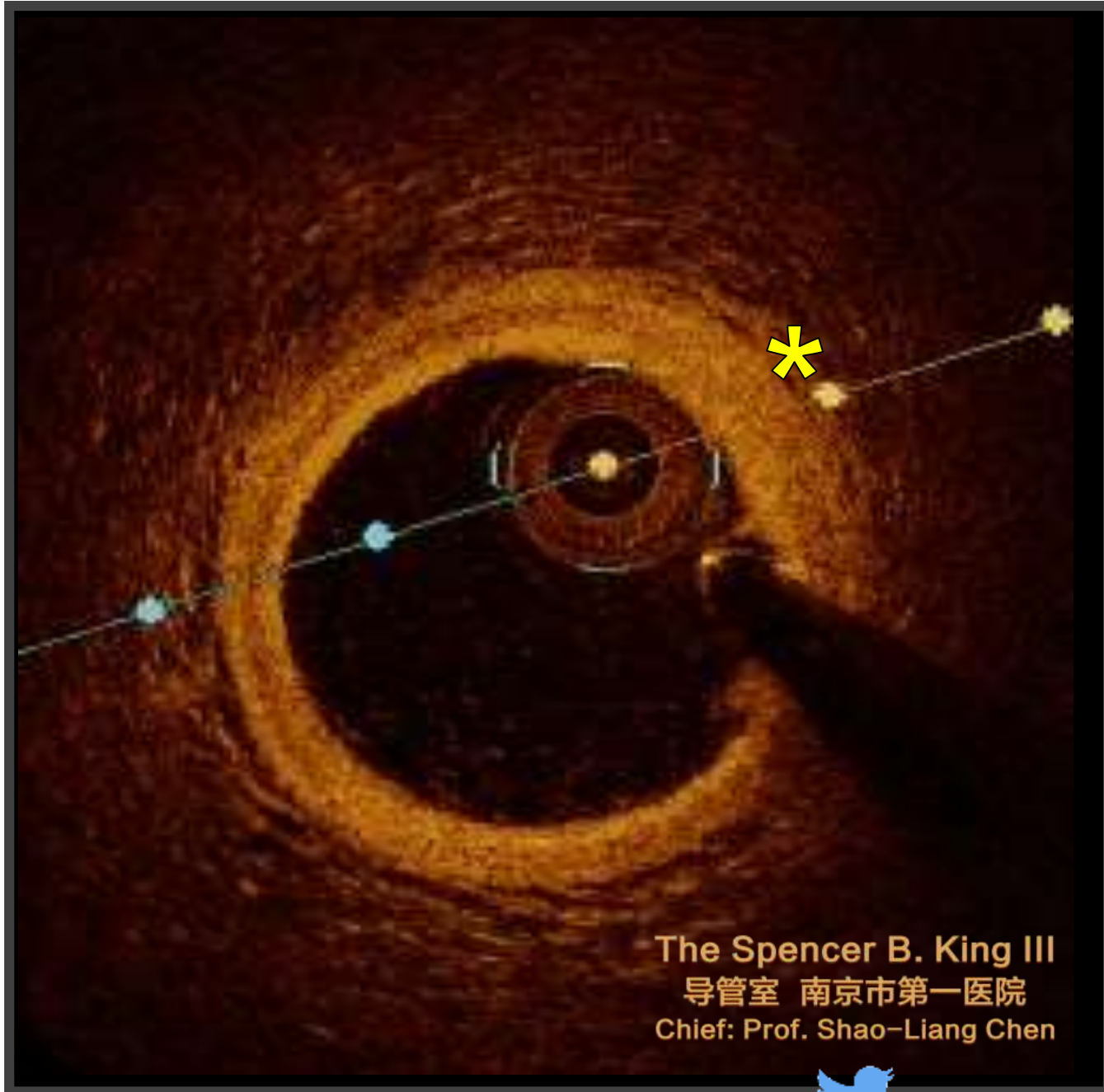
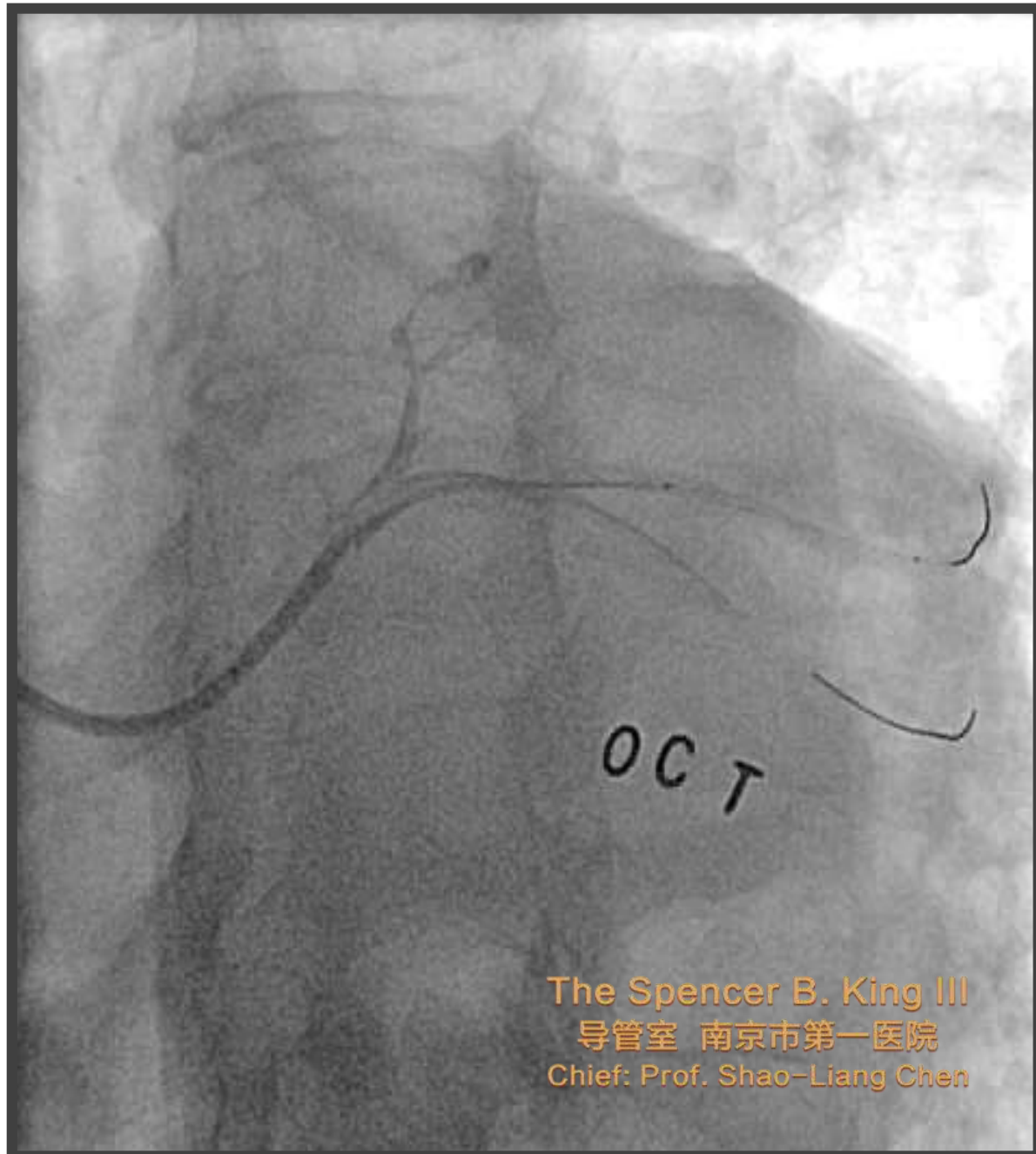














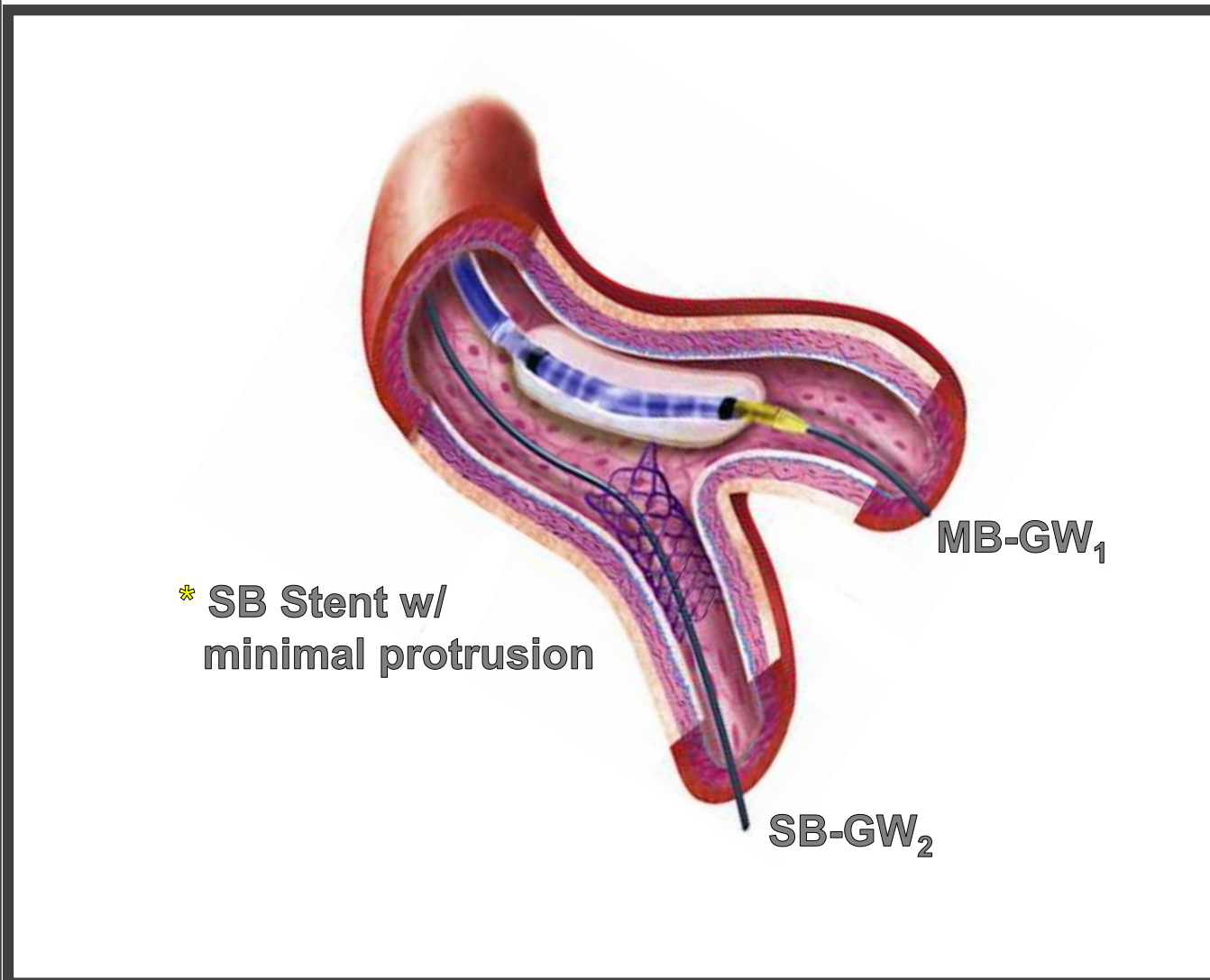
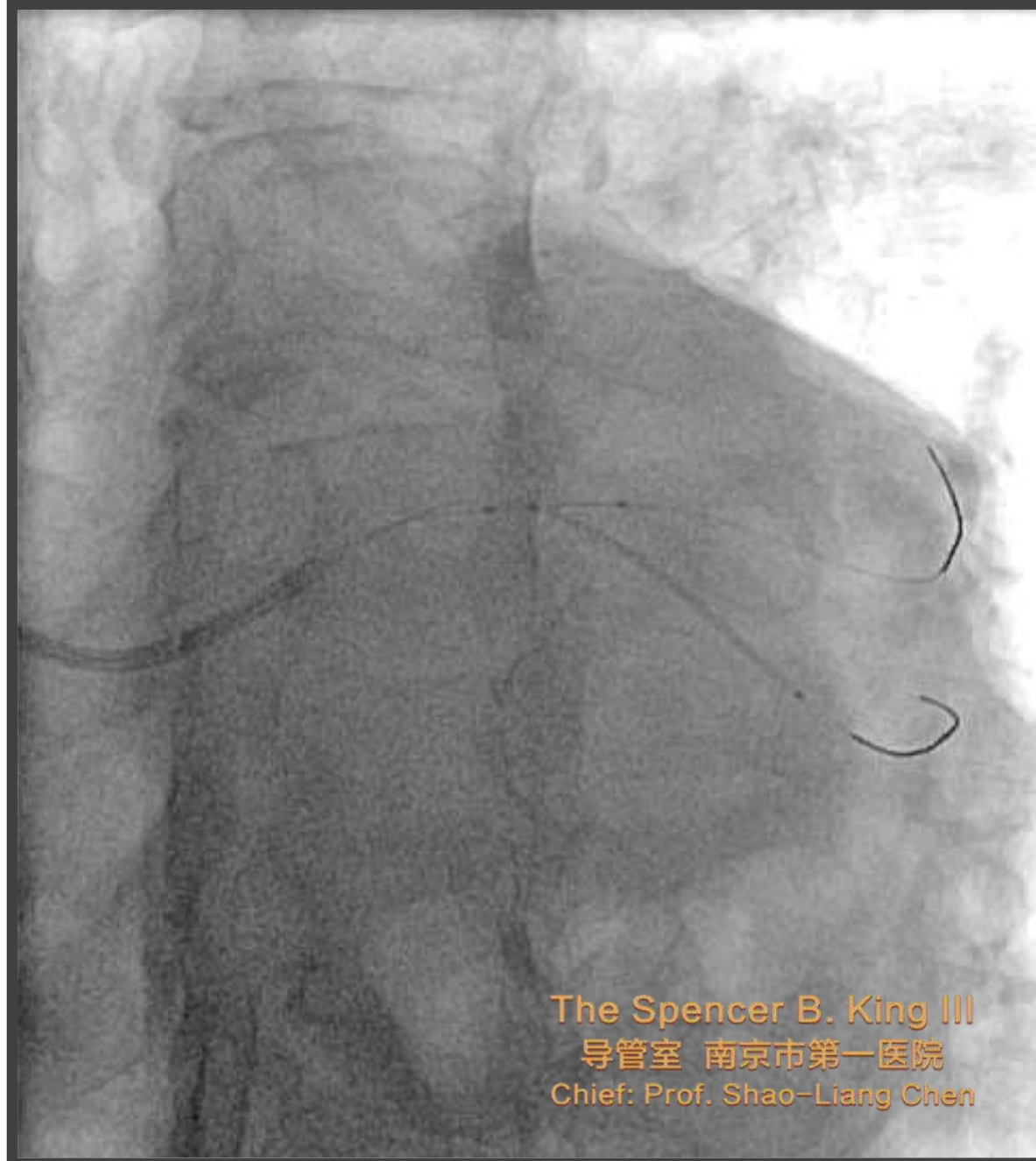The Spencer B. King III
导管室 南京市第一医院
Chief: Prof. Shao-Liang Chen

The 3rd Complex PCI Forum
Nov 30, Lunch Meeting, Room 1, B2
Seoul, South Korea

Switching Strategy: From 1- to 2-stent Technique



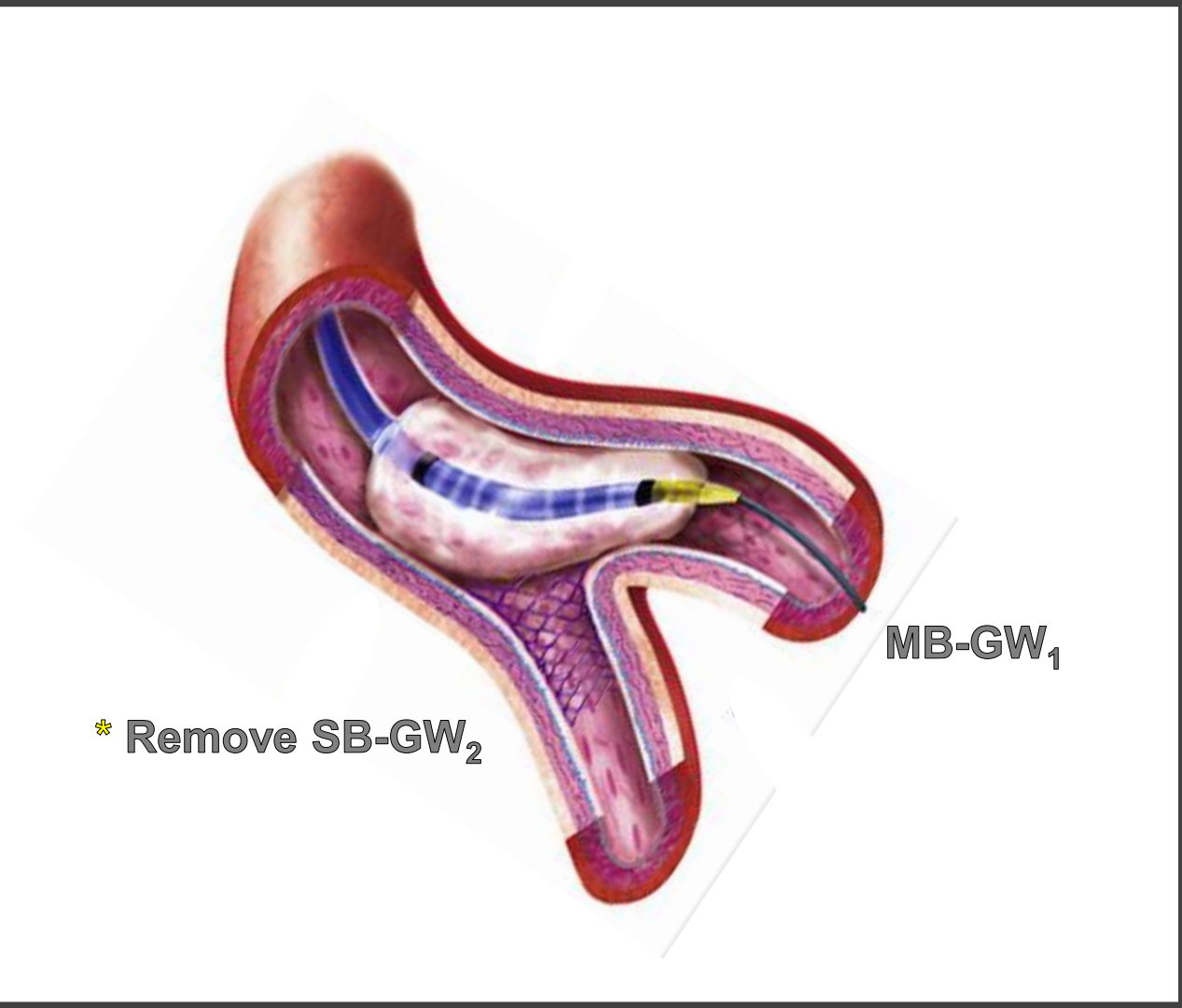
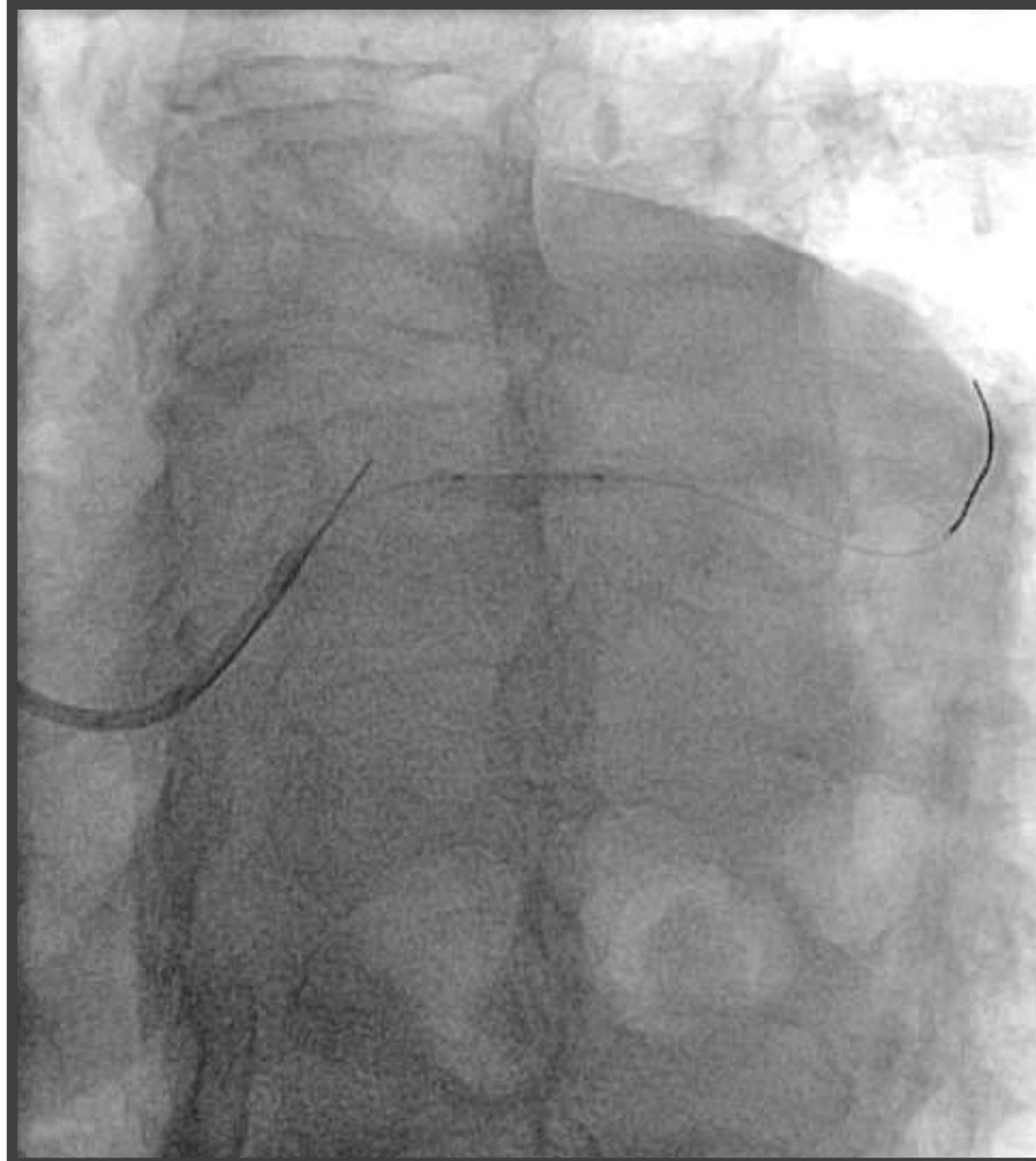
1. Balloon in the MV and stent the SB



J Am Coll Cardiol Interv 2016;9:1861–78



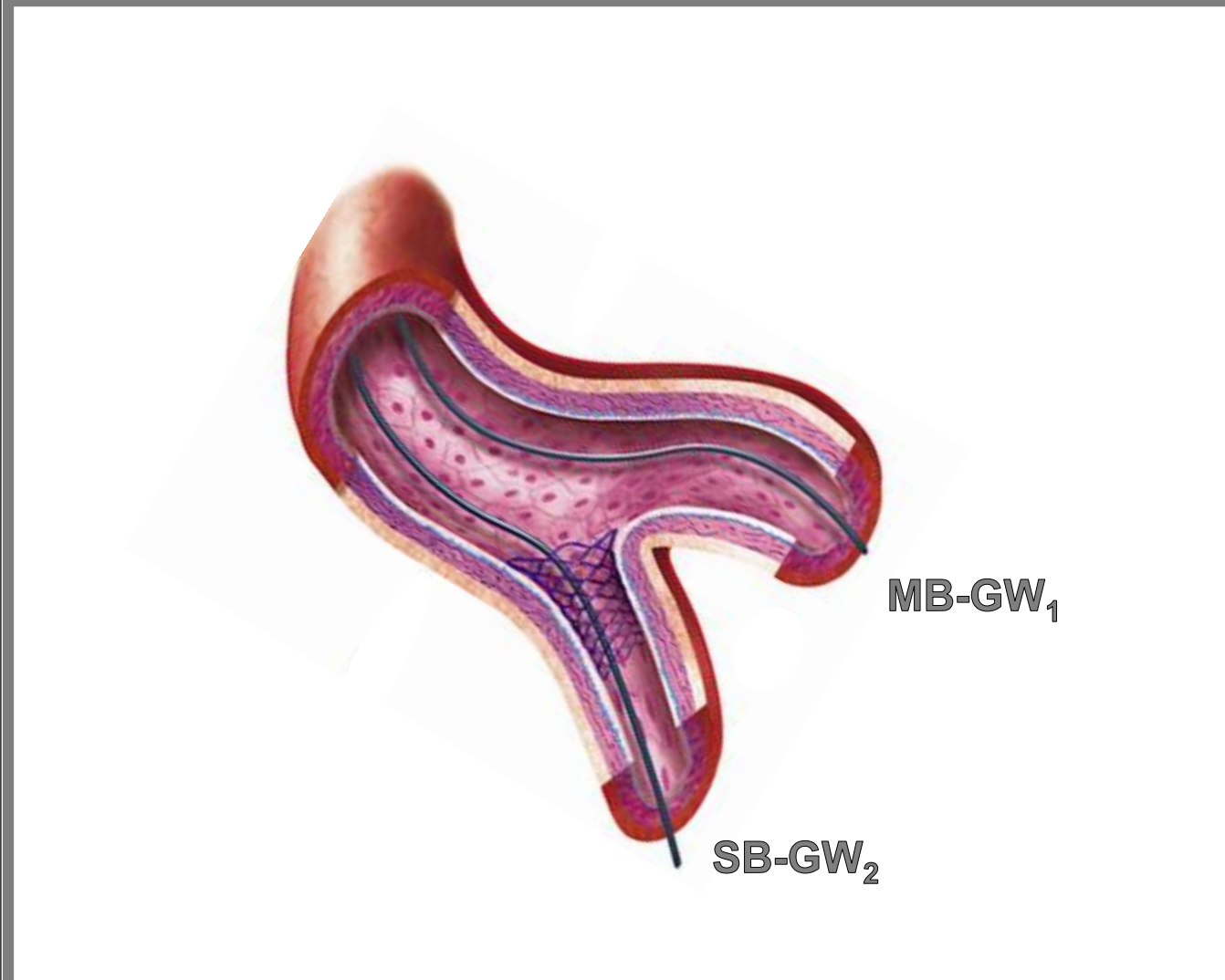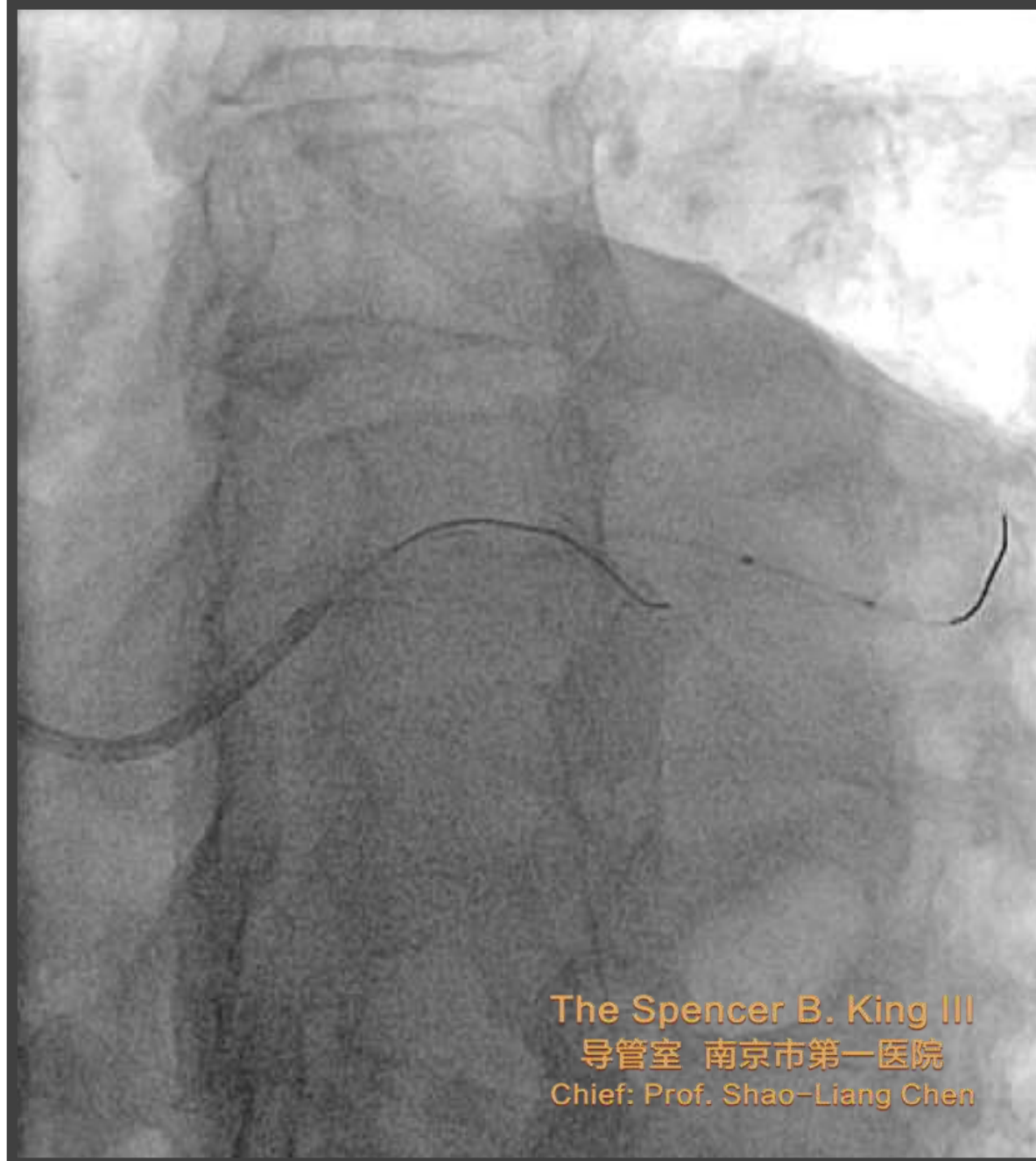2. MV Balloon inflation to Crush the SB Stent



J Am Coll Cardiol Intv 2016;9:1861–78



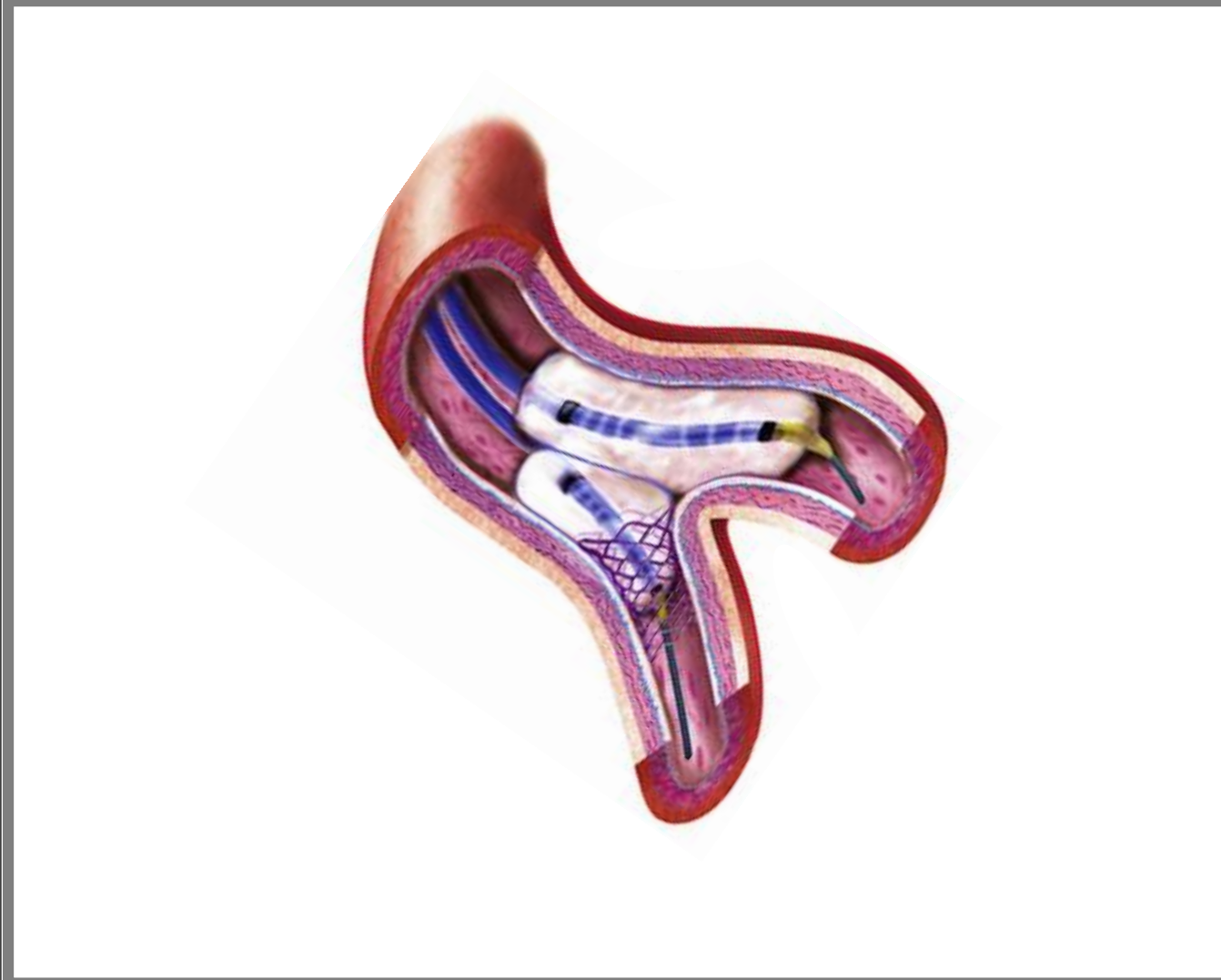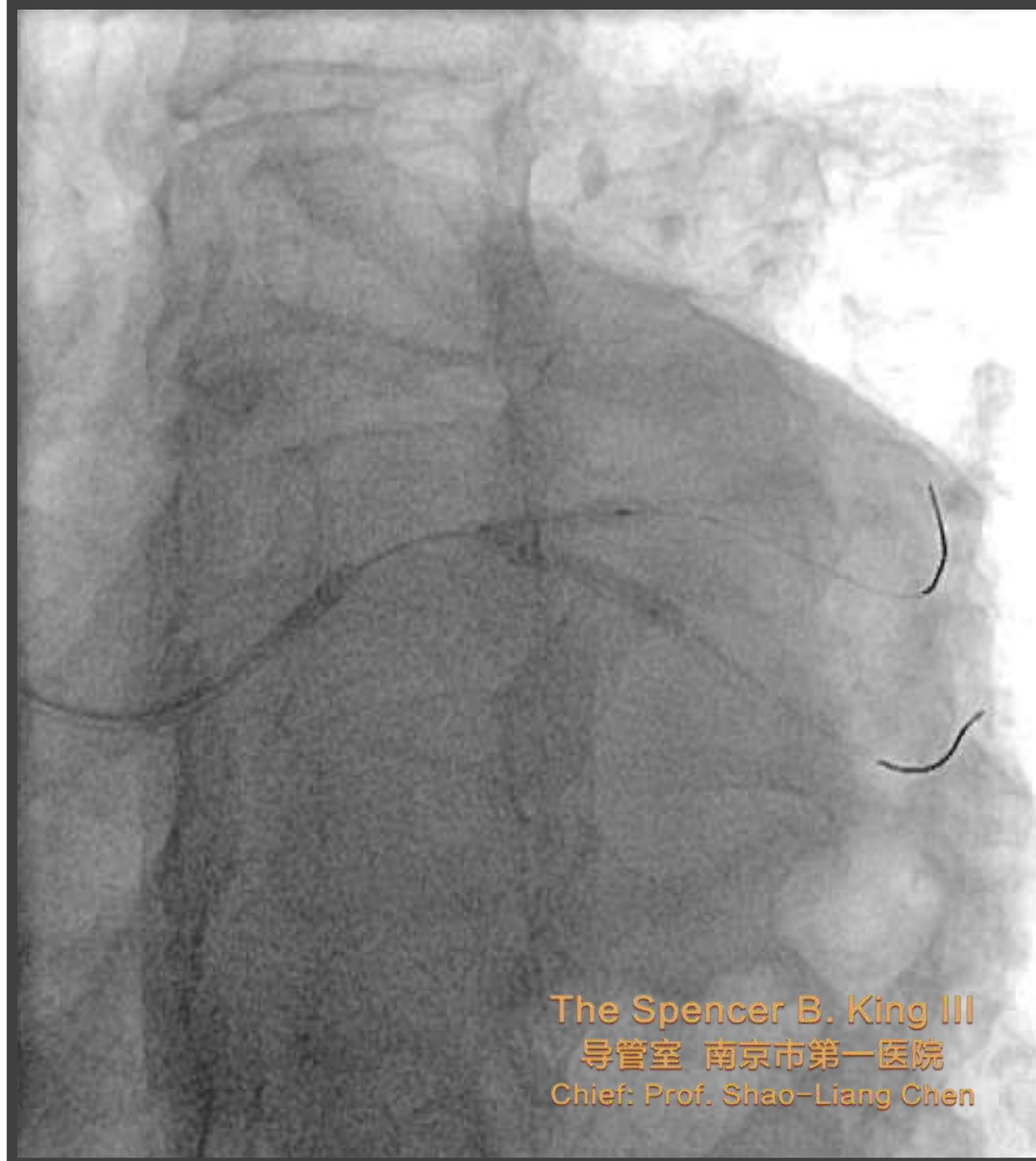3. Proximal Rewiring of the SB



J Am Coll Cardiol Interv 2016;9:1861–78



4. 1st Kissing Balloon Inflation

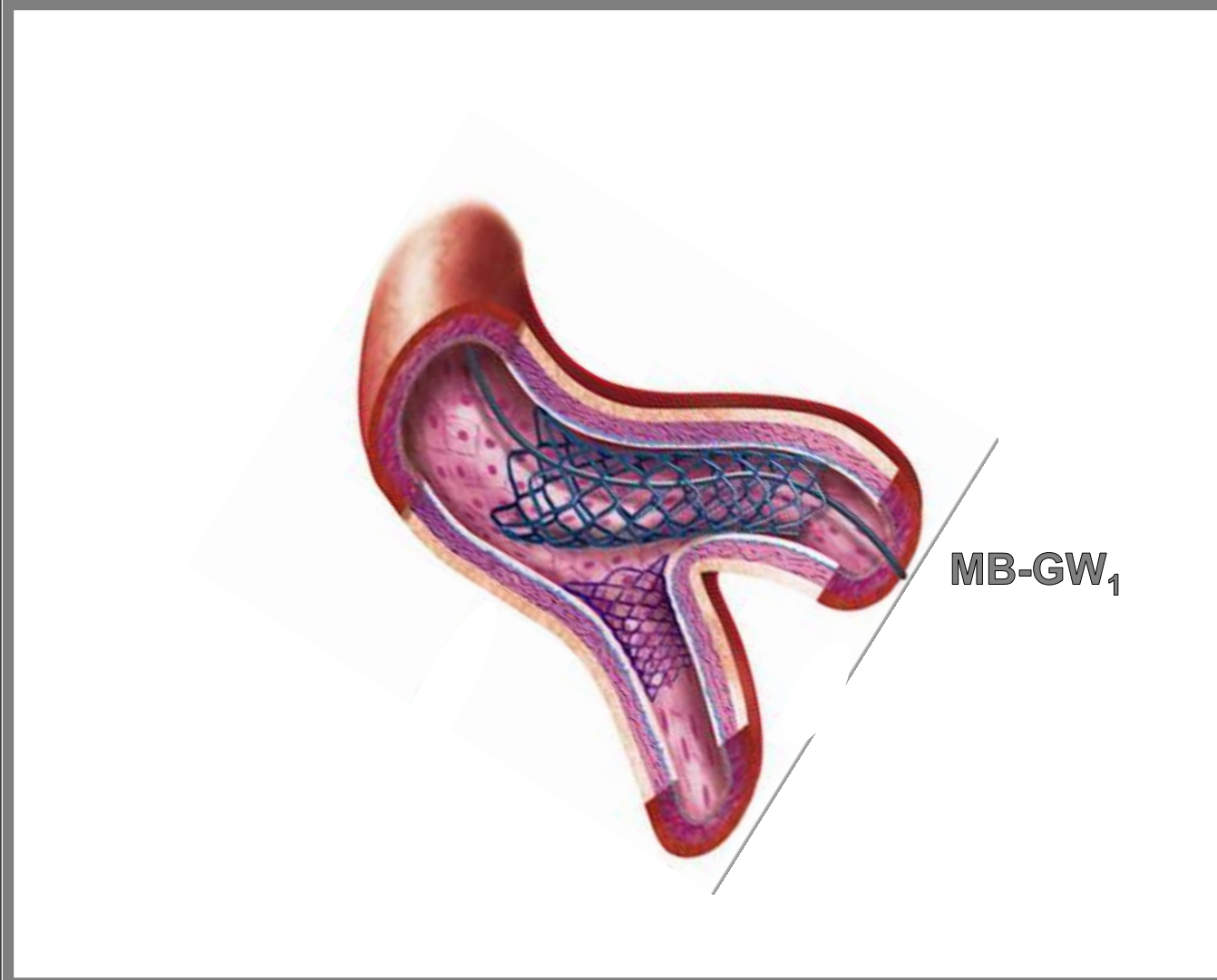
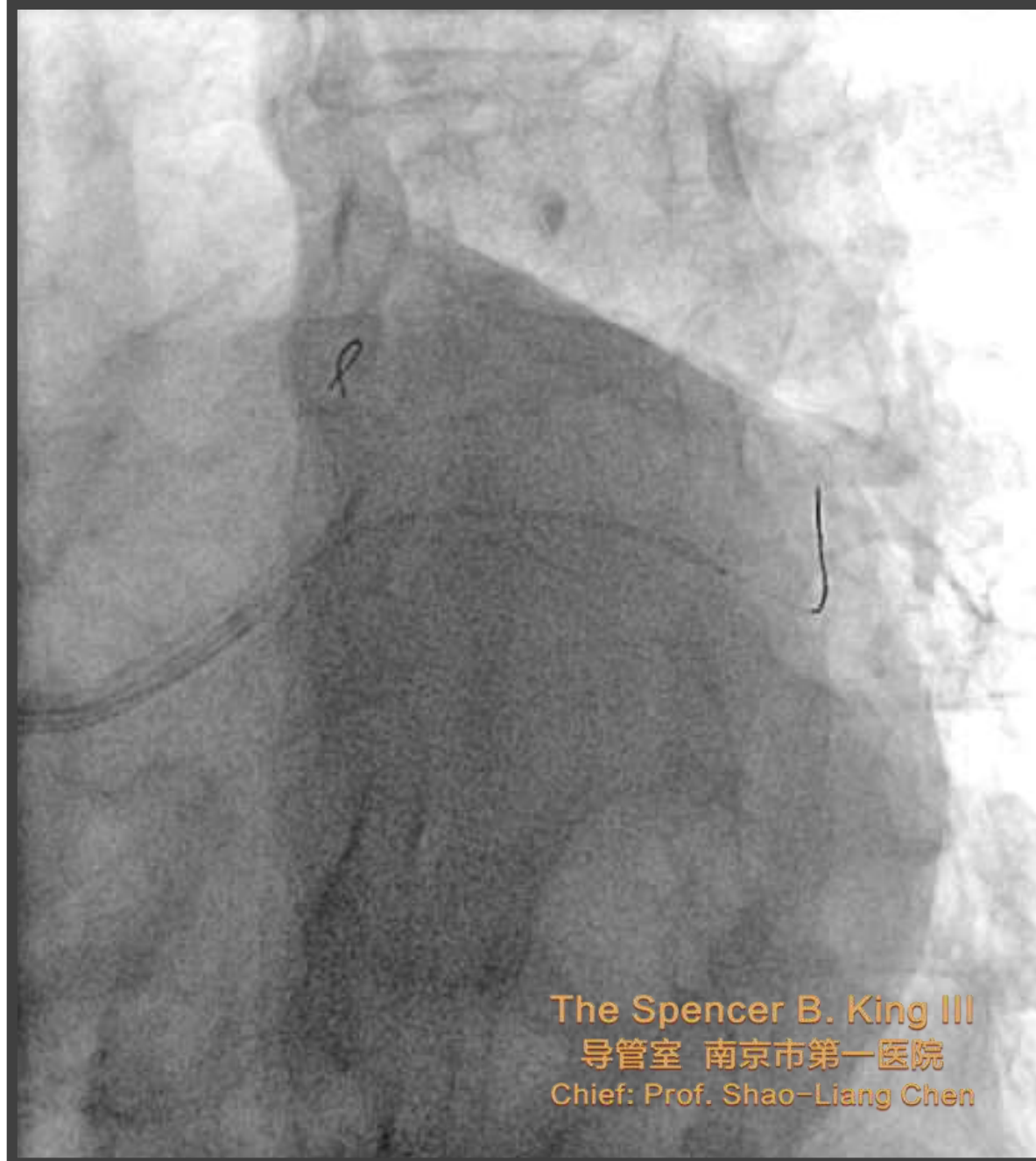

J Am Coll Cardiol Intv 2016;9:1861–78



@bgmdphd

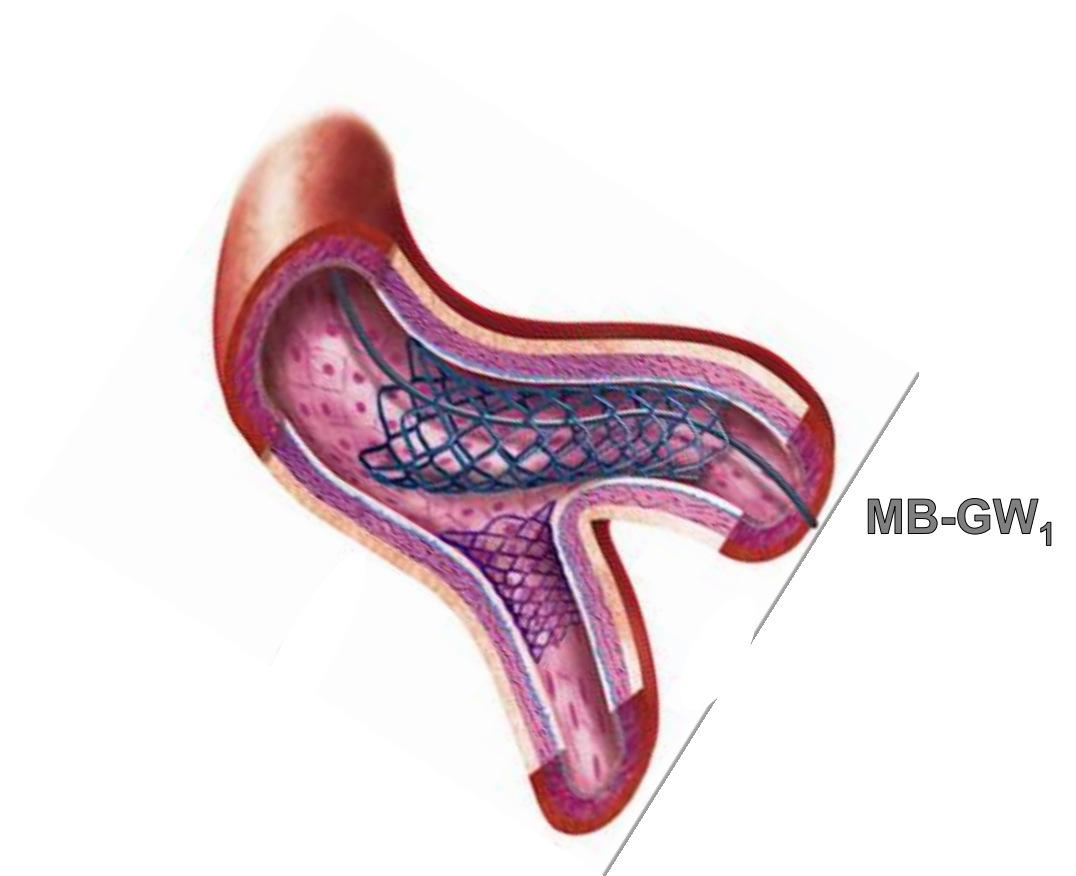
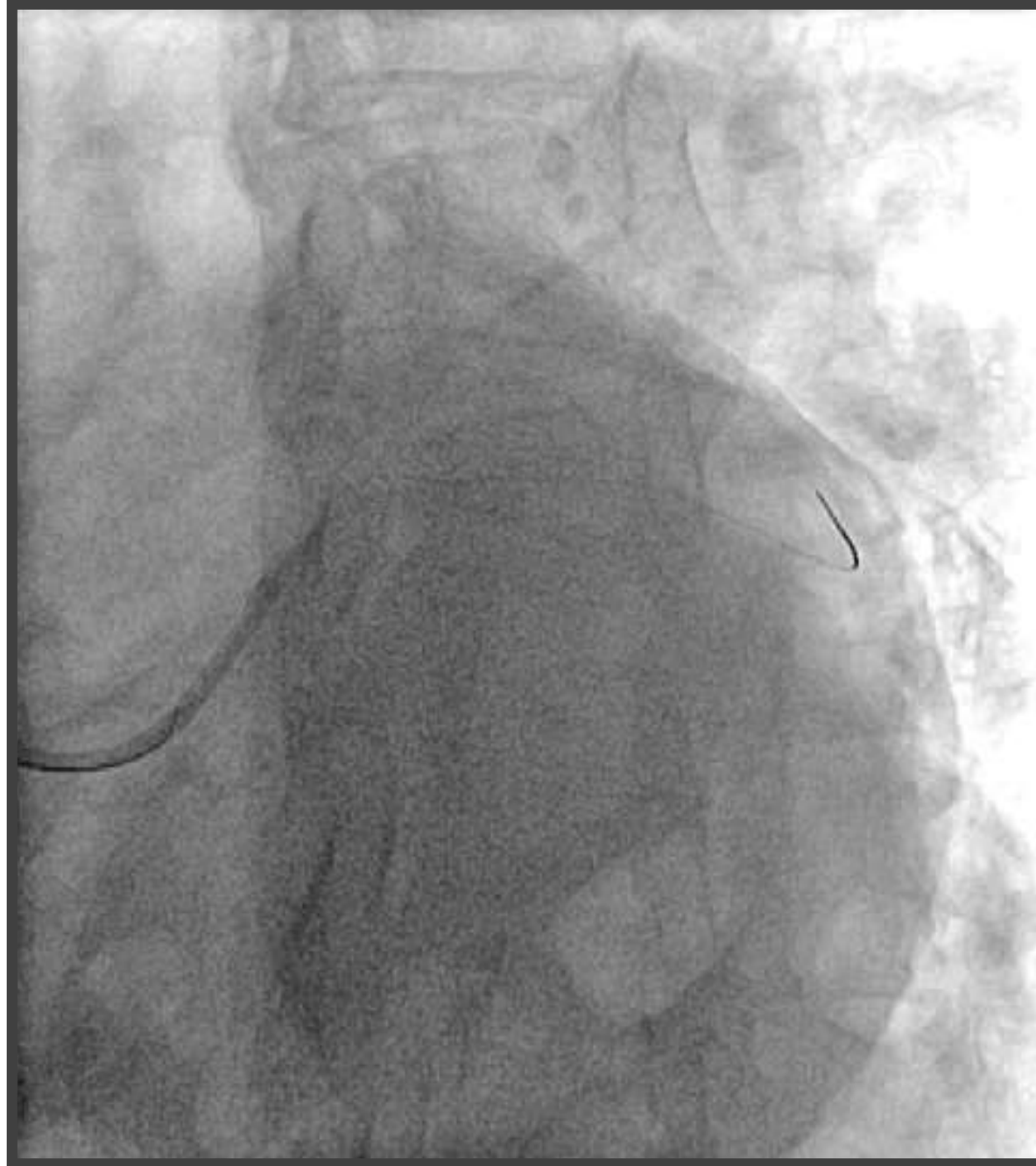5. MB Stenting



J Am Coll Cardiol Interv 2016;9:1861–78



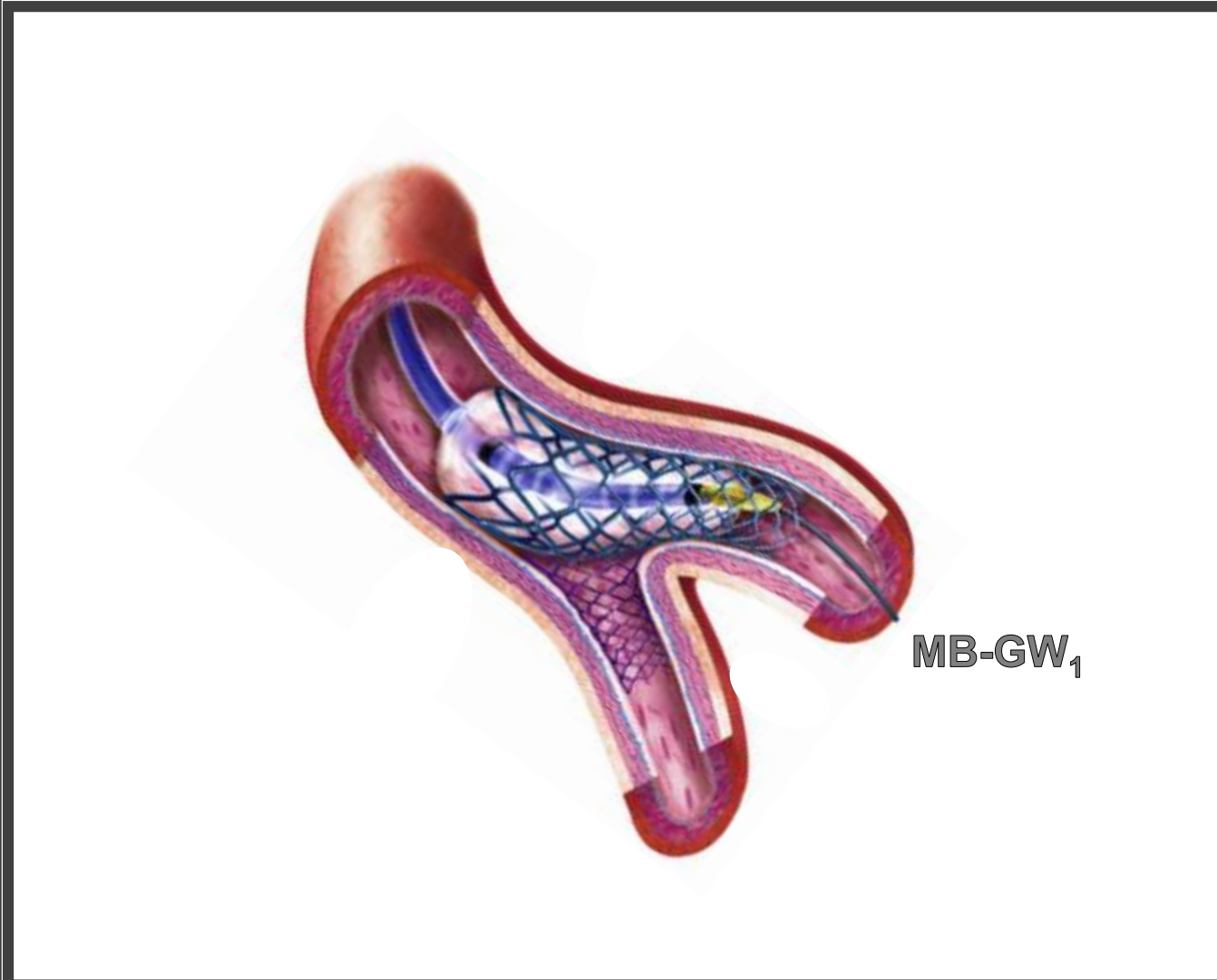
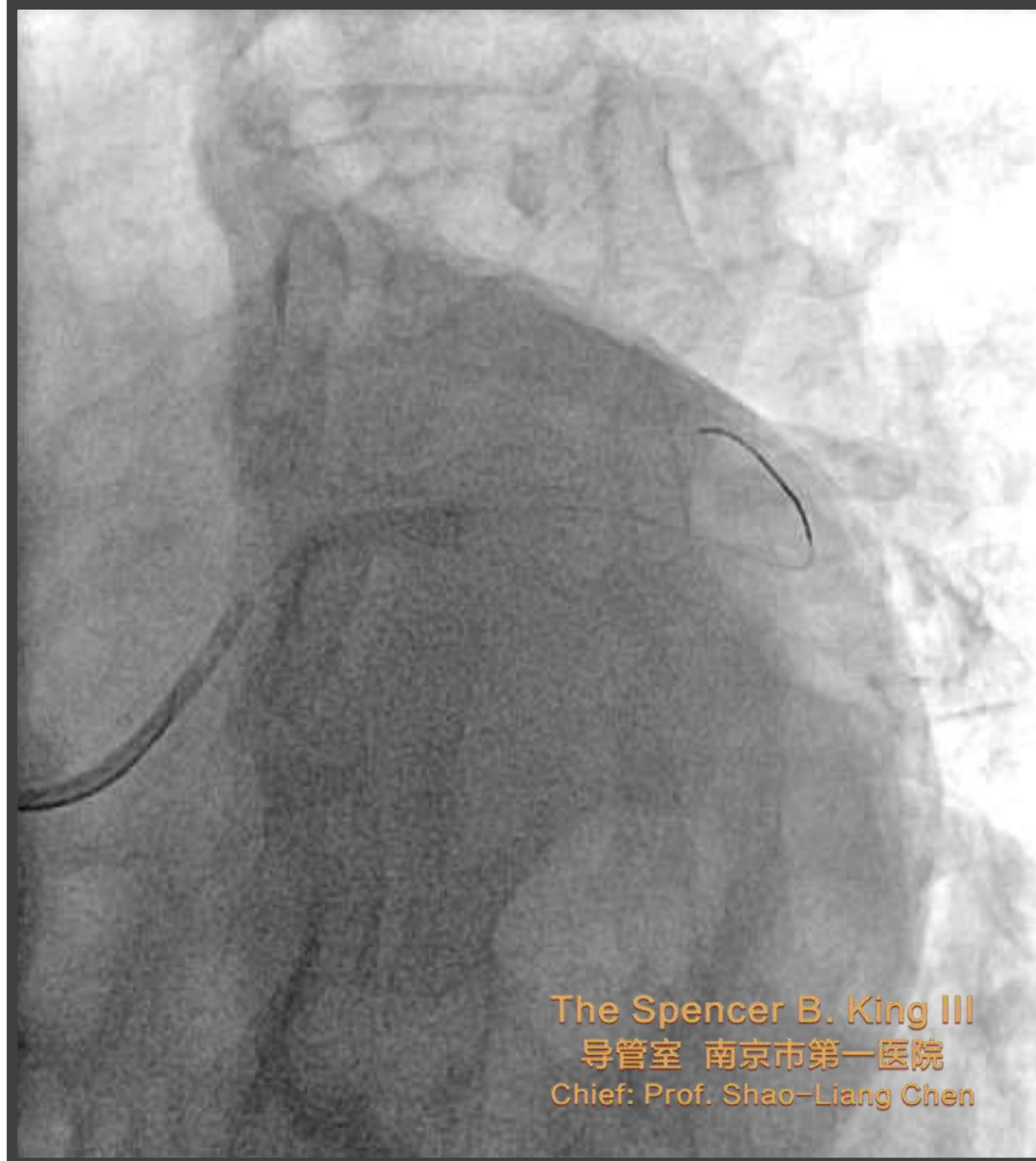5. MB Stenting



J Am Coll Cardiol Interv 2016;9:1861–78



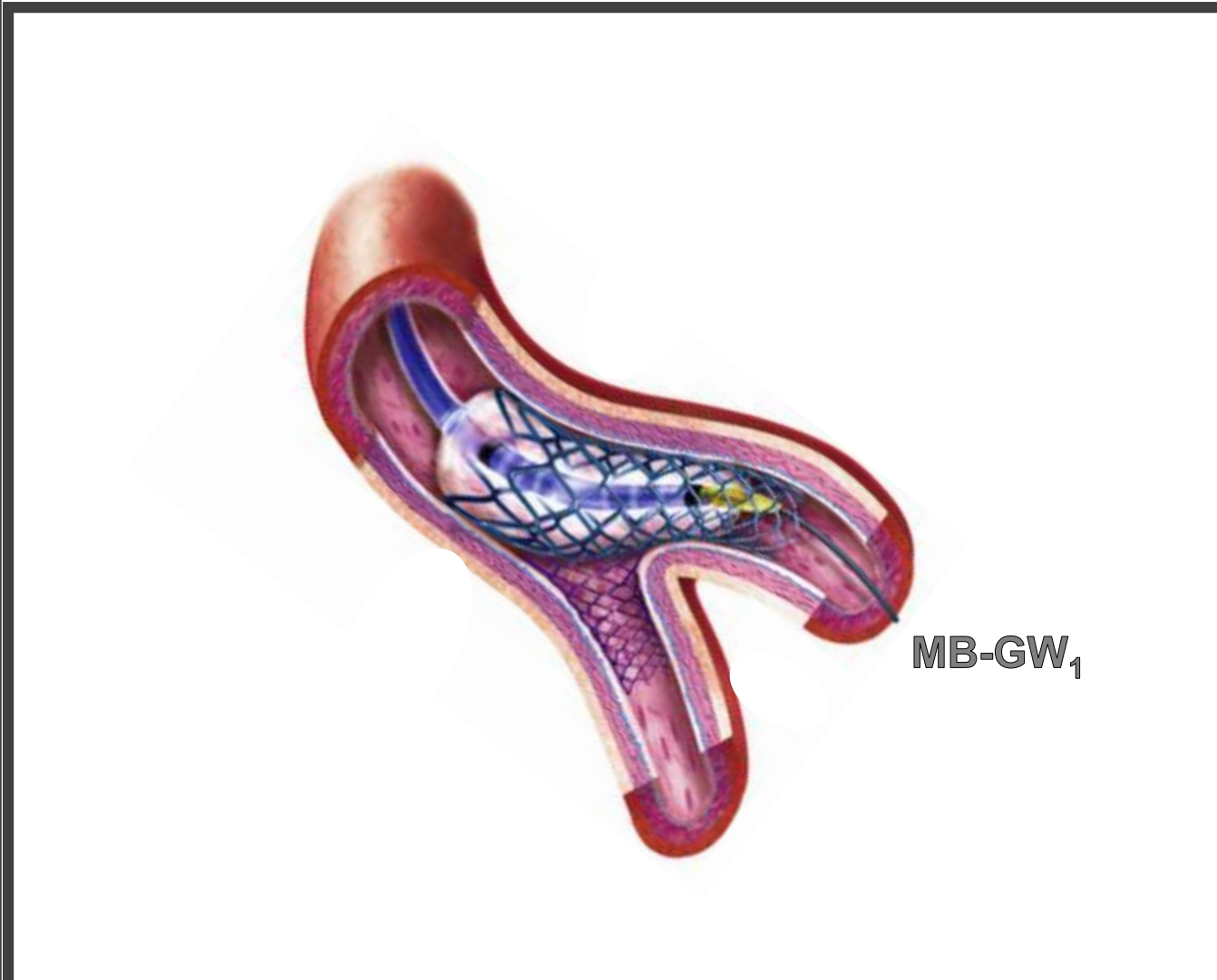
6. POT



J Am Coll Cardiol Intv 2016;9:1861–78



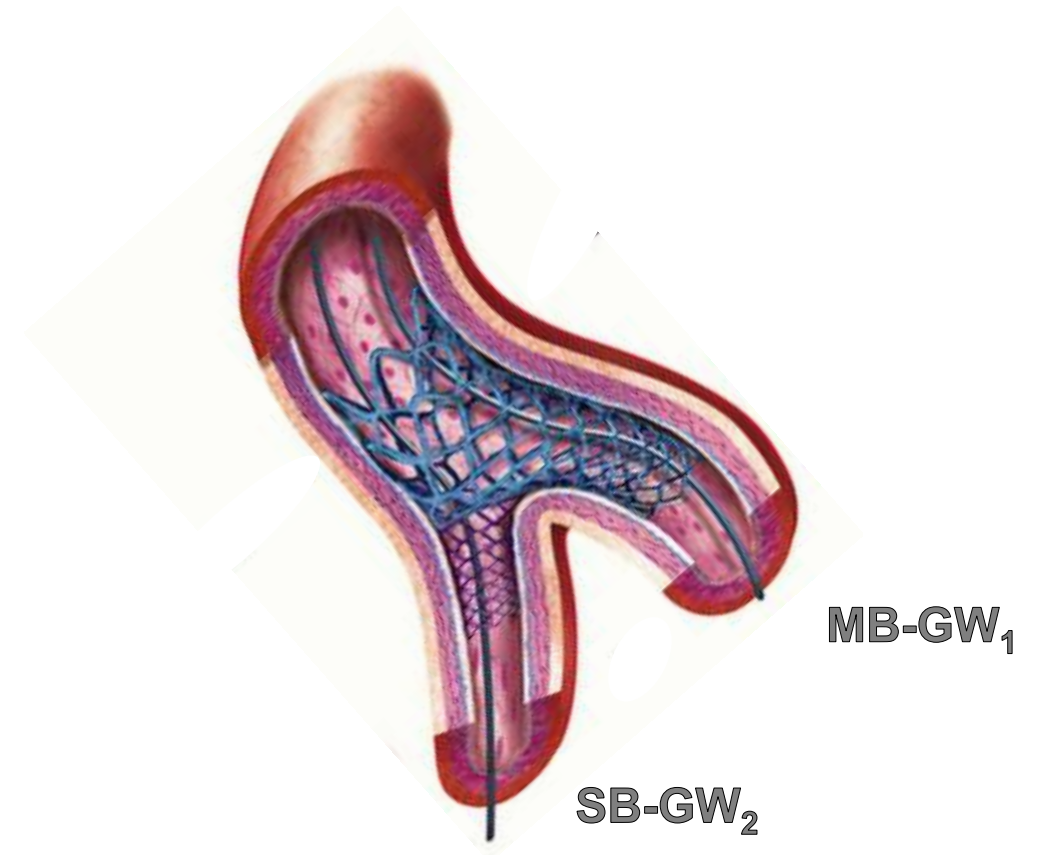
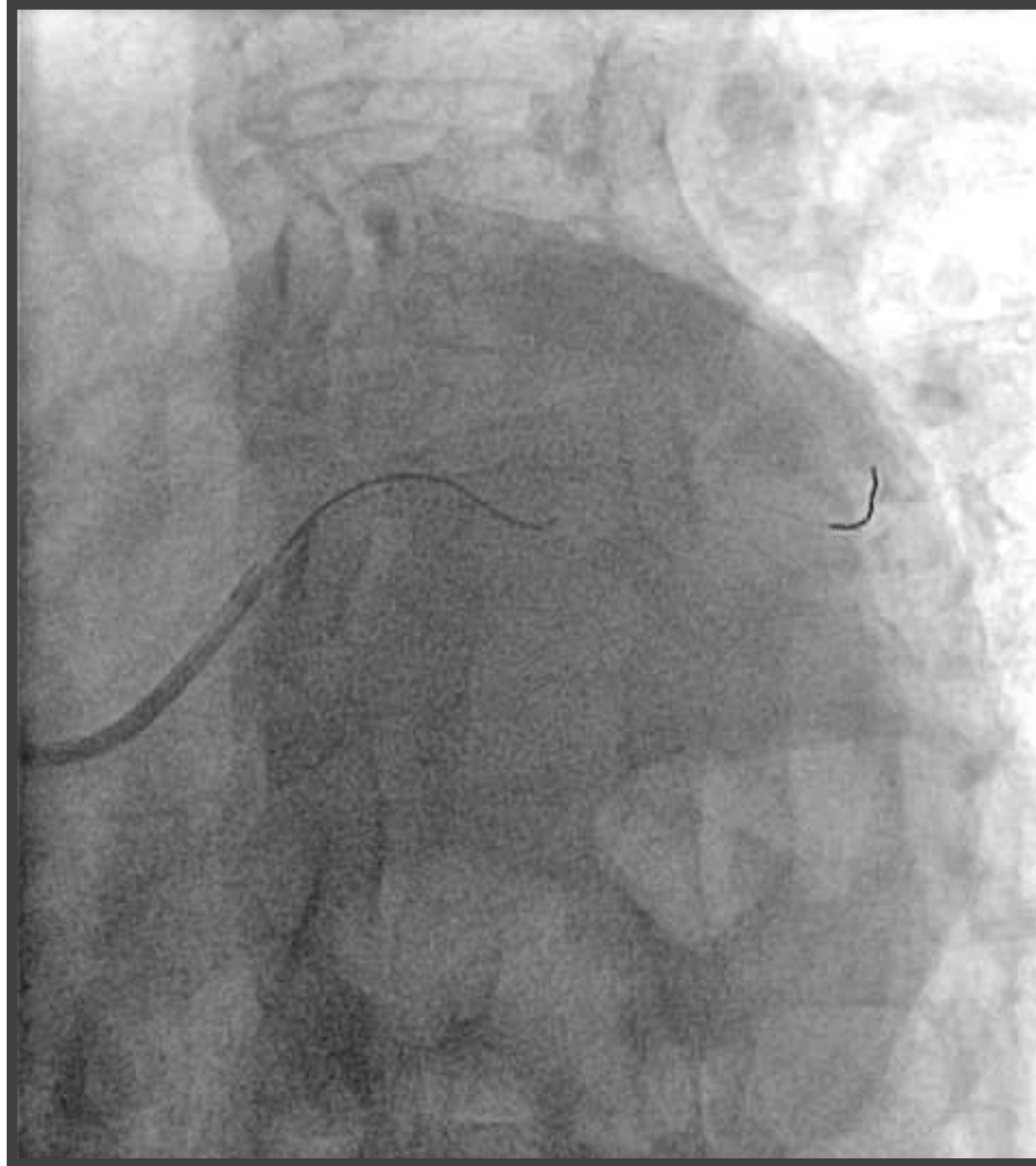6. POT



J Am Coll Cardiol Intv 2016;9:1861–78



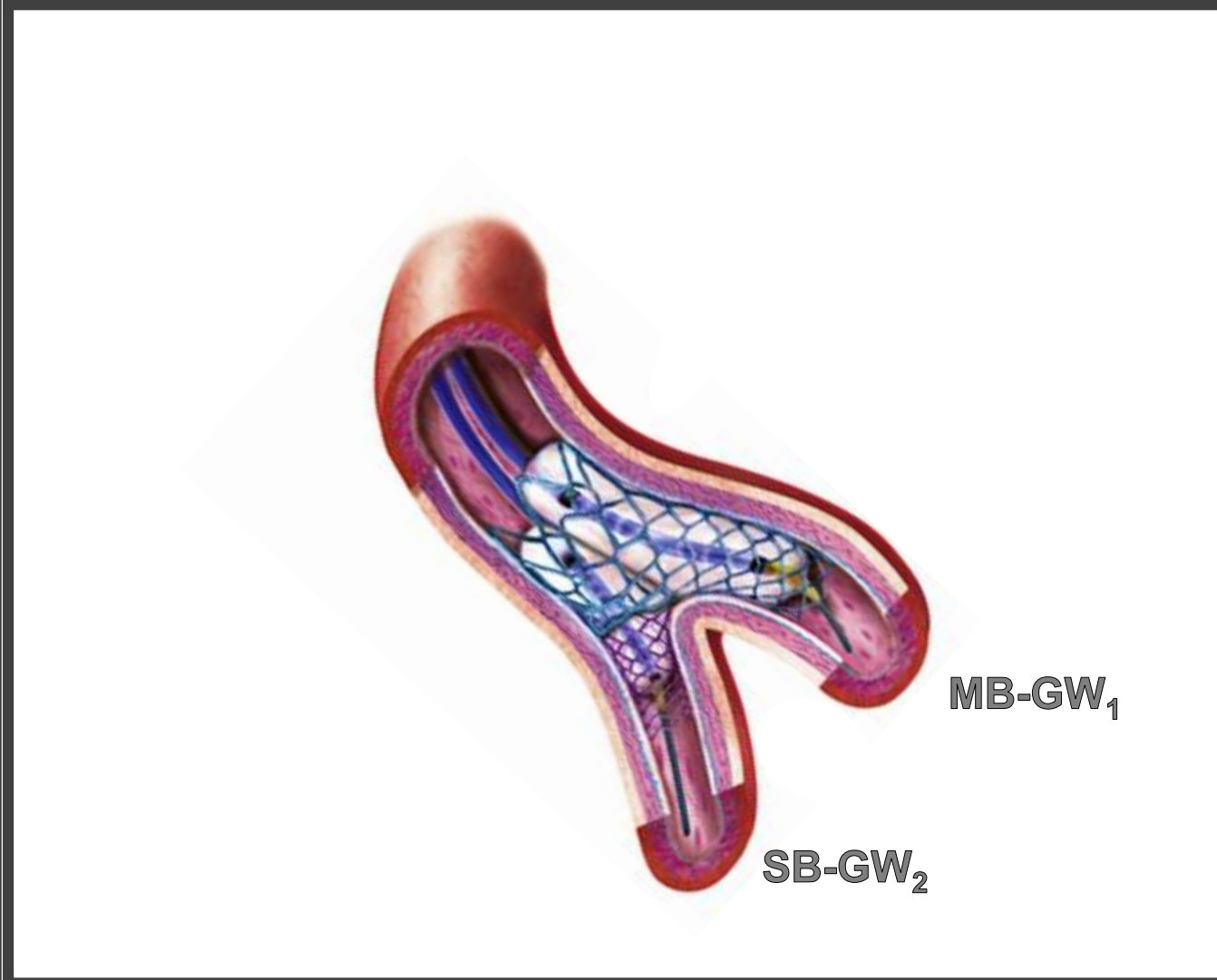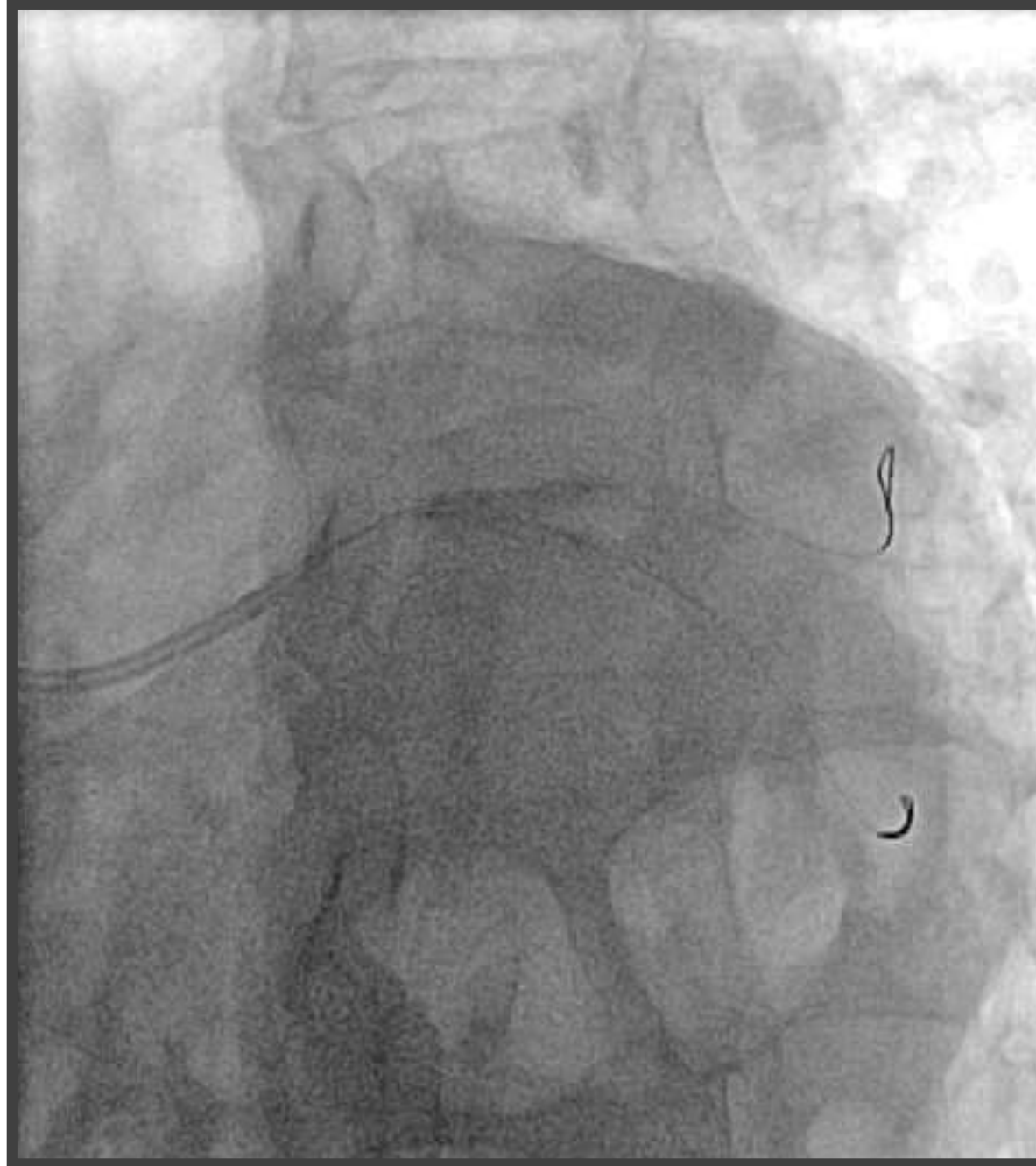7. SB Rewiring



J Am Coll Cardiol Interv 2016;9:1861–78



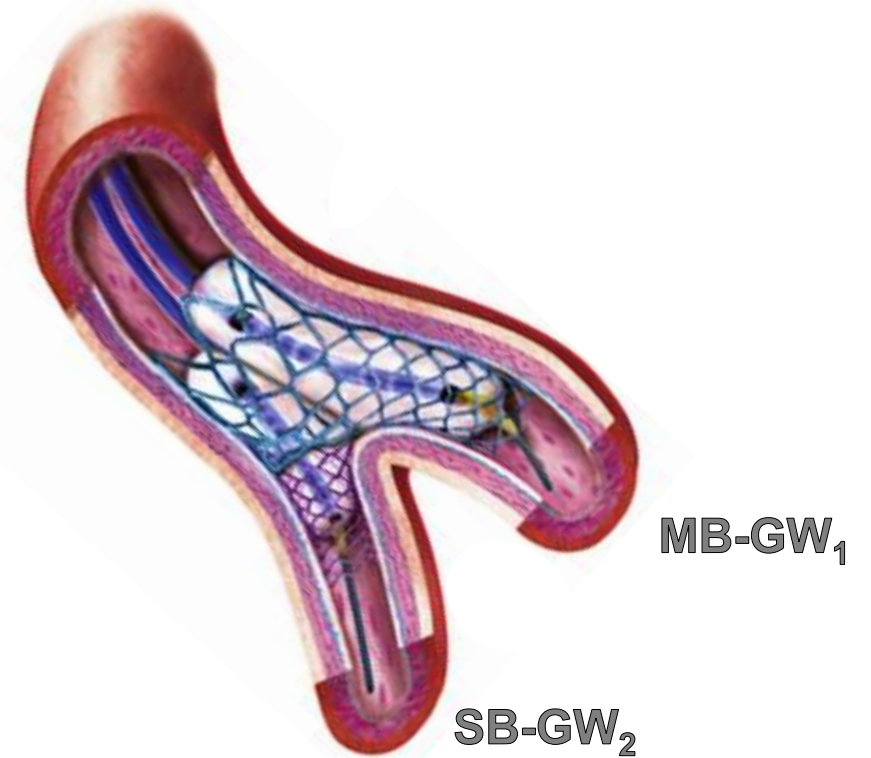
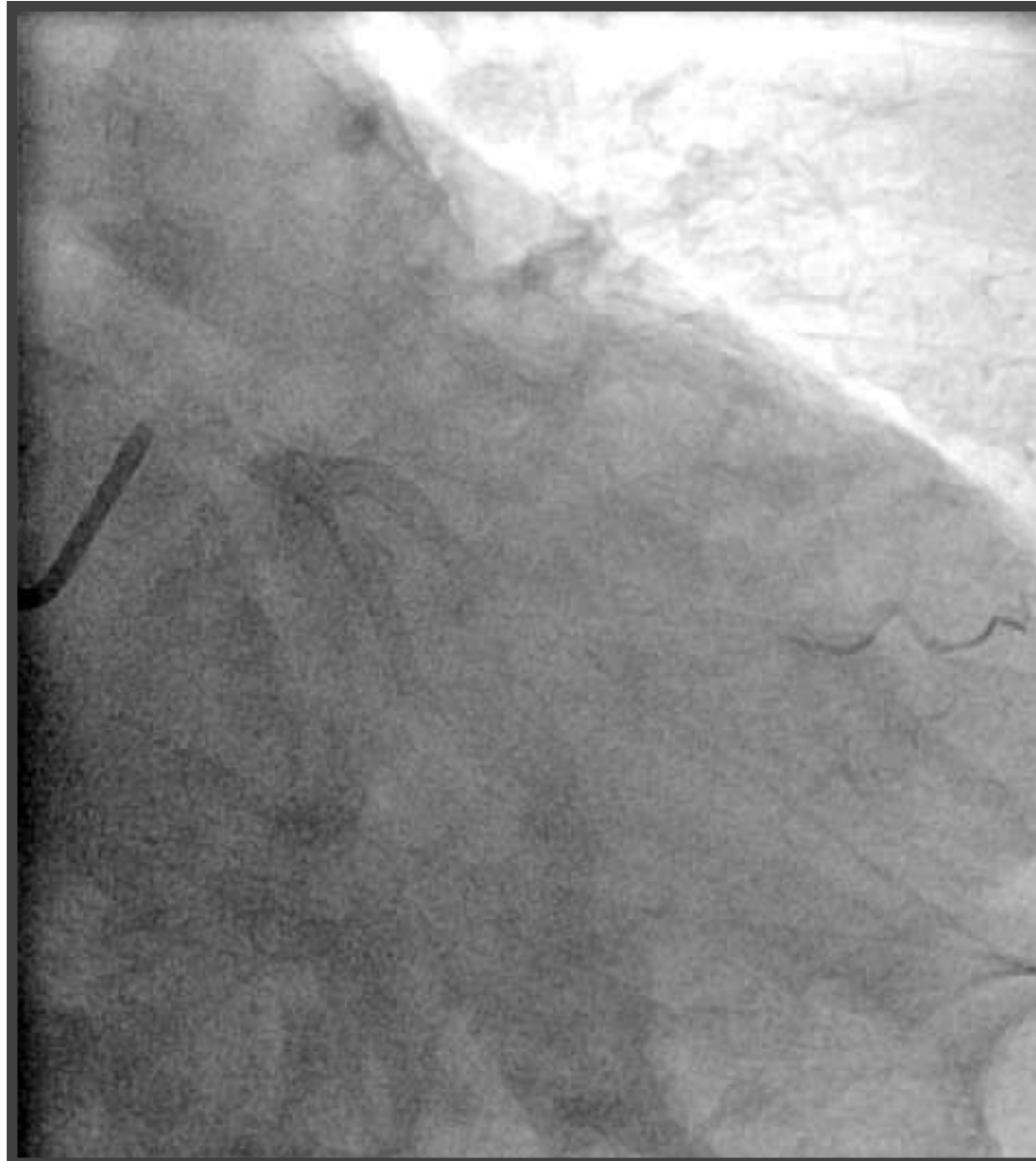8. 2nd KBI



J Am Coll Cardiol Interv 2016;9:1861–78



9. Re-POT / 10. Final Result



J Am Coll Cardiol Intv 2016;9:1861–78





The Spencer B. King III
导管室 南京市第一医院
Chief: Prof. Shao-Liang Chen

The 3rd Complex PCI Forum
Nov 30, Lunch Meeting, Room 1, B2
Seoul, South Korea

Take Home Messages

**Adjunctive imaging, mandatory to guide treatment in
ambiguous anatomy**

**DK Crush is the most relevant 2 stent strategy when
switching from 1- to 2-stent strategy**

